

Case Report

DOI: 10.62046/gijams.2024.v02i01.001

Twelve Years Success of Radiographical Assessment and Clinical Review of Post Periapical Surgery of a Tooth with Canal Calcification (Case Study)

Nazih Shaban Mustafa^{1*}, Sayfaldeen Kashmoola²

¹Associate Professor, Department of Oral Maxillofacial Surgery and Oral Diagnosis, Kulliyah of Dentistry, International Islamic University Malaysia, Kuantan, Pahang, Malaysia

²Qaiwan International University, Prosthodontics DClindent (Prostho)

*Corresponding Author: Nazih Shaban Mustafa | Received: 29.11.2023 | Accepted: 25.12.2023 | Published: 03.01.2024

Abstract: This case report deliberates on the modification of the treatment plan for a young female patient having a history of trauma to her anterior tooth for two years duration. The patient didn't pay attention to the trauma at that time and she barely remember about it, until she gets in pain. In this case study we will highlight on the treatment options and how to save the tooth. Different modality of treatment has been raised to study the possibility of the survival of this tooth since the patient doesn't want to lose it.

Keywords: periapical surgery, success rate, assessment, canal calcification, case study.

Citation: Nazih Shaban Mustafa & Sayfaldeen Kashmoola. Twelve Years Success of Radiographical Assessment and Clinical Review of Post Periapical Surgery of a Tooth with Canal Calcification (Case Study). Grn Int J Apl Med Sci, 2024 Jan-Feb 2(1): 1-8.

INTRODUCTION

Adults suffer traumatic dental injury at significantly lower rates compare with the younger individuals who are most frequently affected by dental trauma. Crown fractures are most reported for the permanent teeth, while luxation injuries in the primary dentition. Diverse types of injuries require proper diagnosis, treatment planning and follow up. In traumatic dental injuries, it is crucial to verify a promising outcome [1-4]. Proper history taken about the type, duration signs and symptoms of trauma play a key role in verbalizing the type of treatment and the success rate. The outcome of any surgical treatment is determined as a result by the duration of the follow-up after the procedure in each surgery. This case scenario presents the follow up of a patient with a history of trauma associated with pain at the upper left anterior incisor region for twelve-year duration.

CASE REPORT

A 22 – year -old female patient attended the oral surgery specialist clinic at Faculty of Dentistry International Islamic University Malaysia (IIUM) with the complaint of pain and discomfort upon mastication in her 21 tooth area, she claimed that she had a history of trauma in the past two years. Intra oral examination revealed that tooth 21 tender to percussion with localised erythematous tender gum labially.

Case History

A 22-year-old female patient with a history of trauma of two years duration, presented with pain in the upper anterior left region, the pain is localized, the score was 7 /10 increasing by mastication, which makes the patient unable to eat. The duration of pain is about one week. The pain started as a mild type of pain then gradually increased to reach the mentioned score. The patient took paracetamol herself for three days before attending the clinic.

She claimed that she had a history of trauma, but she cannot remember the details, she can recall that only there was a mild gum bleeding from 21 area at the time of trauma which stopped simultaneously, and the patient did not seek any treatment at that time.

Extra oral examination revealed no asymmetry or abnormality, intral oral examination demonstrated localized erythematous non elevated tender on palpation labial gingiva adjacent to the tooth 21. The tooth 21 was tender to percussion and the results of vitality tests, cold and EP test showed that the tooth is non vital, and mildly discoloured. Patient sent for periapical radiograph which showed a localized radiolucency at the apical area, with thickened lamina dura of 21 and a completely obliterated canal.

After the examination and investigations obtained the patient was, diagnosed with apical periodontitis. The patient received three treatment options, which were.

1. Periapical surgery,
2. Conservative treatment by, excluding the tooth 21 from occlusion through selective grinding to prevent pain and protect the tooth, in addition to pain killer and broad-spectrum antibiotics with metronidazole,
3. Extraction of 21 and placement of implant.

After explaining of each of the treatment options in details, the patient agreed to do periapical surgery of the lesion with apical resection.

Outcome

Curettage was performed with resection 90° angle of the apical part of the root, the procedure was successful without any complications. The patient informed to come to the clinic periodically every 6 months for review. At each visit, the patient has been examined clinically and inquired about any signs and symptoms such as pain, swelling, or discomfort, as well as that patient sent for panoramic and periapical x-ray. Unfortunately, the patient was not able to attend as required and she came yearly or after more than one year. The following figures (1-4) presenting the panoramic radiographic and the figures (5-11) shows a periapical radiographic appearance of the tooth 21 and the surrounding structures for twelve years duration after surgery.

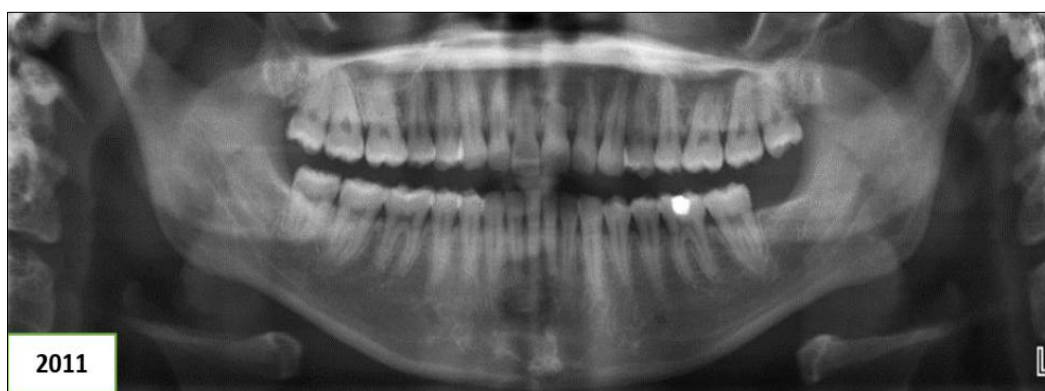

Figure 1: OPG One Year after Surgery Year (2011)

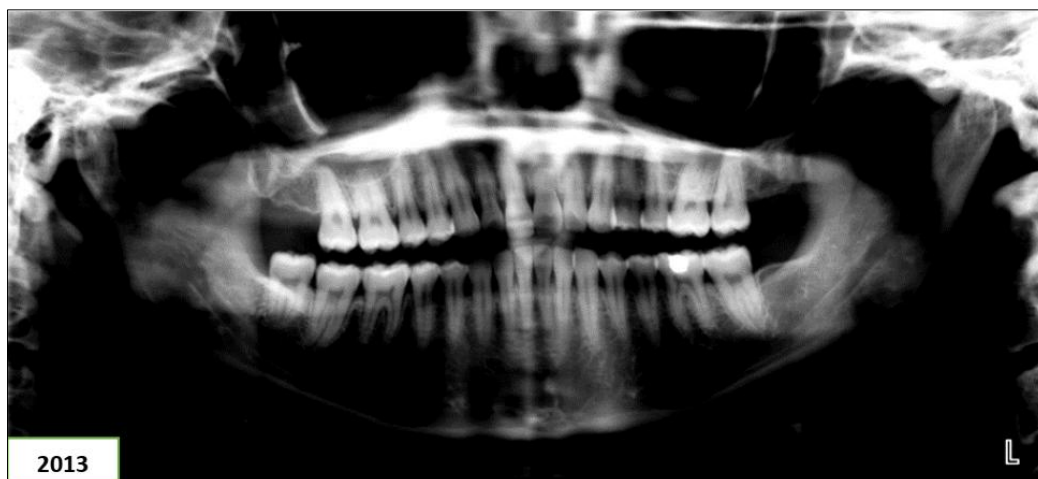

Figure 2: OPG Three Years after Surgery Year (2013)

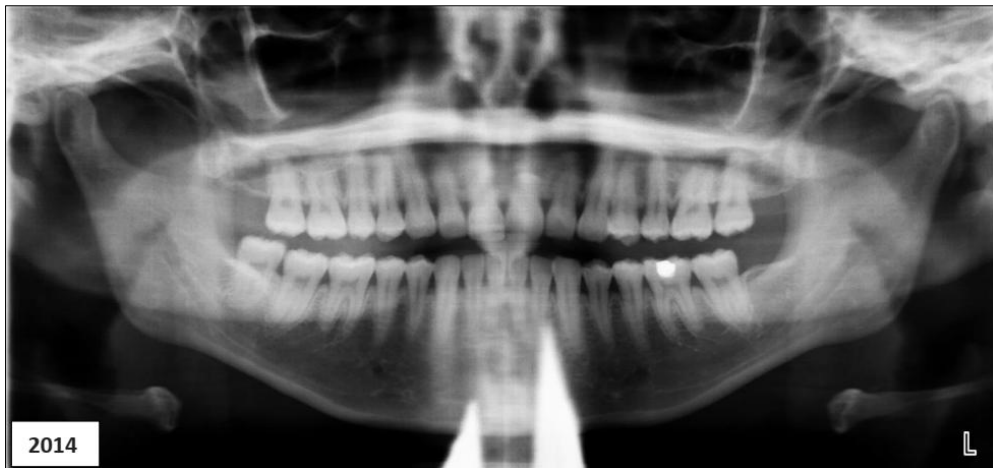


Figure 3: OPG Four Years after Surgery Year (2014)

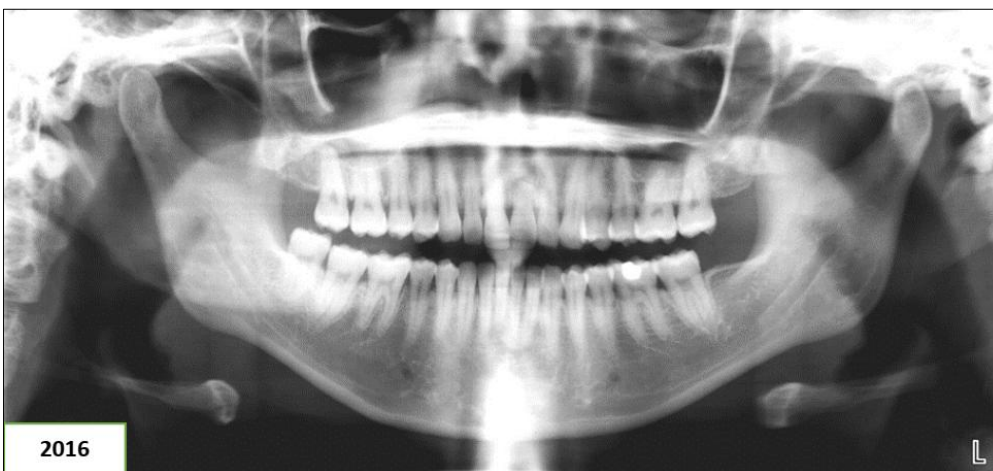

Figure 4: OPG Six Years after Surgery Year (2016)

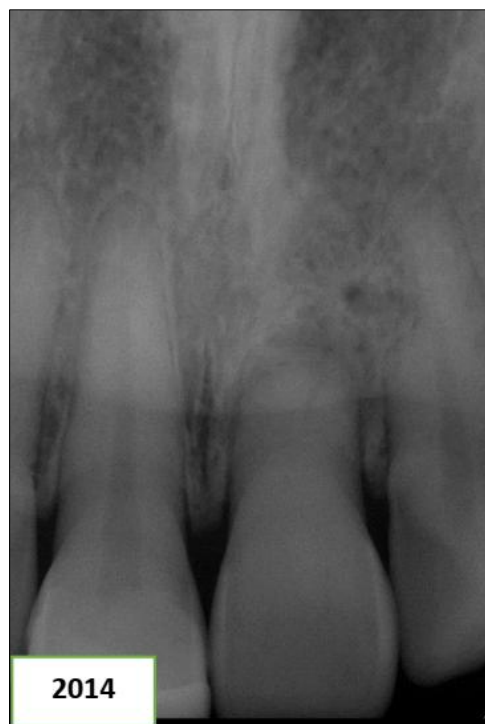

Fig. 5: PA Four Years after Surgery Year 2014

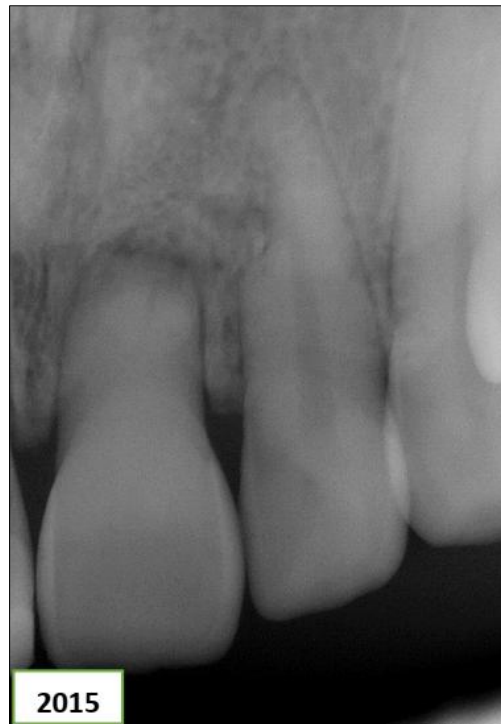

Fig. 6: PA Five Years after Surgery Year 2015

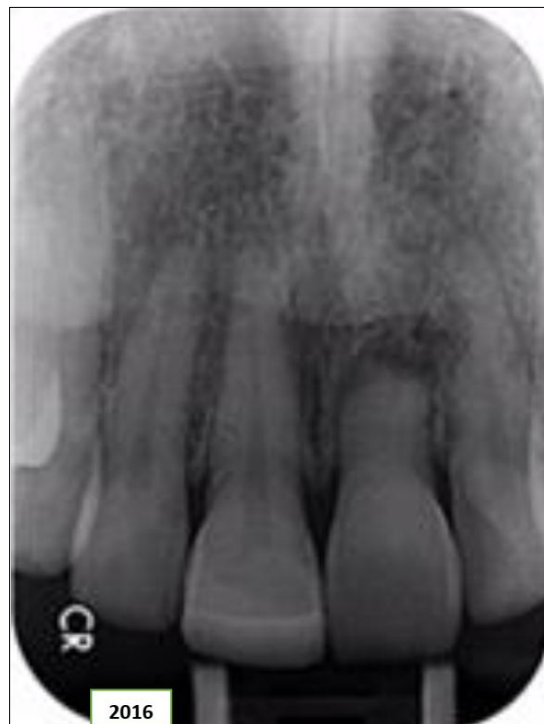

Fig. 7: PA Six Years after Surgery Year 2016

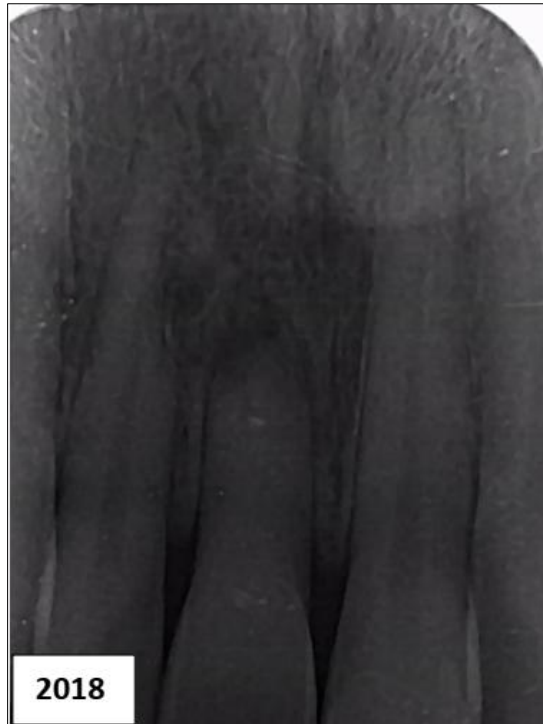

Fig. 8: PA Eight Years after Surgery Year 2018

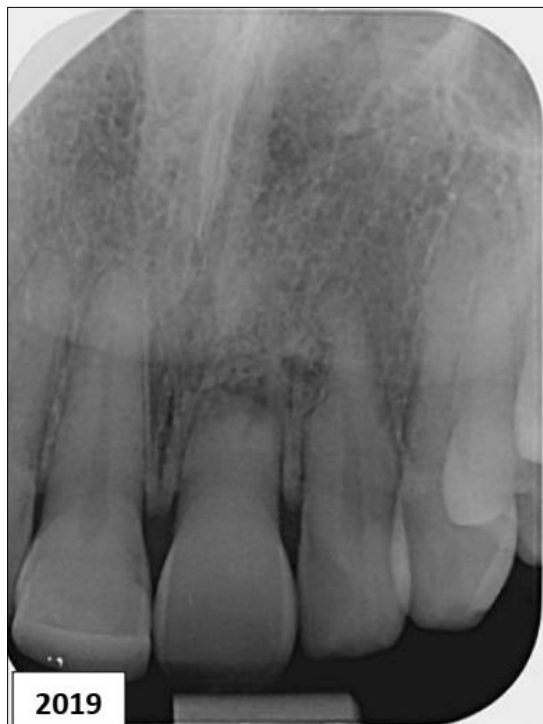

Fig. 9: PA Nine Years after Surgery Year 2019

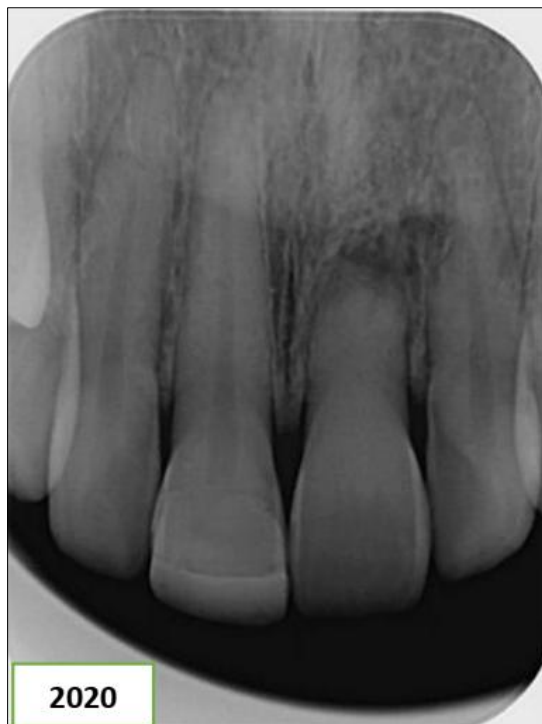

Figure 10: PA Eleven Years after Surgery Year 2020

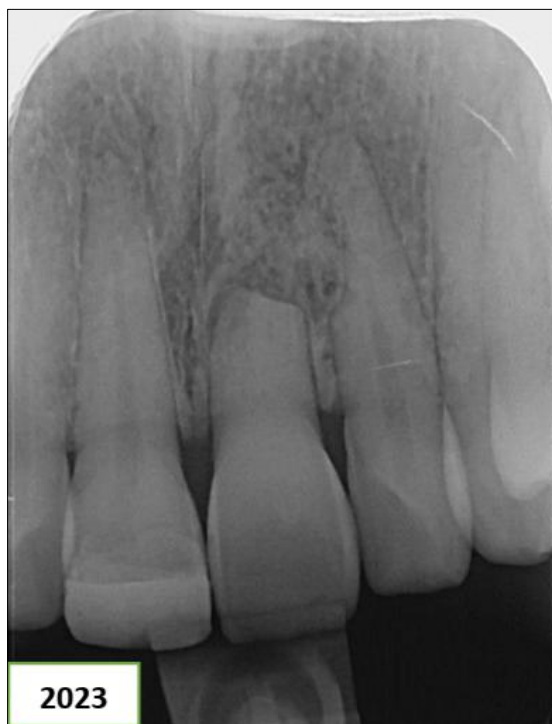

Figure 11: PA Twelve Years after Surgery Year 2023

For the above figure number eleven which is the latest periapical radiograph illustrated, showed a good bone quality at the apical area with no periapical lesion and the root is intact with no remarkable resorption in comparison with the earliest radiographs.

The clinical examination of the patient displays no sign or symptoms of recurrence of the infection the figure number (12) viewing the tooth 21 with mild discoloration, the gum adjacent to the tooth looks healthy with no sign of infection or inflammation on the top of that there is no mobility observed.

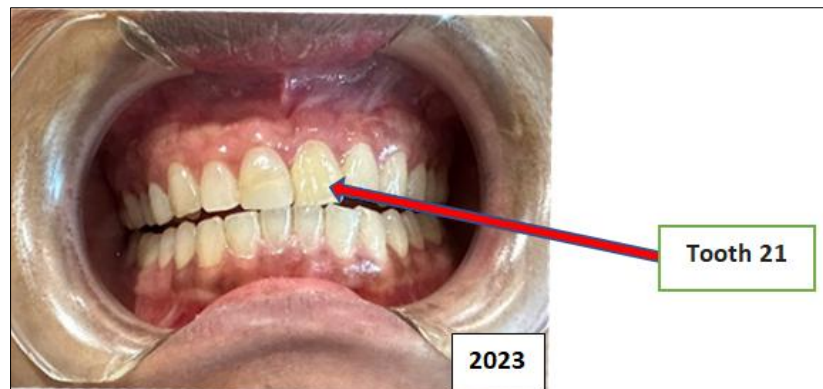


Figure 12: Twelve Years after Surgery Showing Mild Discolouration of the Tooth (21) With A Healthy Surrounding Mucosa, Year 2023.

DISCUSSION

Pulp canal calcification is characterized by the deposition of calcified tissue in the canal walls. As a result, the root canal space can become partially or completely obliterated [5]. Dental pulp calcifications result from accelerated deposition of mineralized tissue into the pulp chamber and root canal system in response to external aggressors, as a result of trauma, orthodontic movements, caries lesions and previous restorative interventions with the use of materials that induce the formation of this mineralized tissue [6]. The most injured teeth in both the primary and permanent dentitions are the maxillary central incisors. The severity of the trauma is varying from simple crown fractures to luxation, subluxations and even avulsions. No significant differences in the severity of traumatic dental injury were reported. As in our case study which is in constant with Lam R. *et al.*, [7], he mentioned that only one-third of the patients presented for dental treatment within 24 hours of the injury, while the remainder delayed seeking treatment for varying times up to 1 year or even more. The reason behind that may be a lack of education regarding the importance of receiving immediate care following the dental trauma of many patients and parents, this makes the management plan more complicated and less successful [8]. Furthermore, accessibility and availability of dental care could be a significant factor in the delay in presenting for care as mentioned by Day PF *et al.* [9]. As the patient takes a long time to appear for the treatment, these patients may be unable to recall what exactly occurred during the injury; this recall prejudice may affect the outcome of the treatment. According to Vinagre *et al.*, [10], he mentioned in his review article that Watchful waiting is the most frequent clinical approach implemented case of obliterated canal teeth, which can be applied in case when there is no sign and symptoms means no complaint. Unlike in our case study, this option cannot be followed since the patient is symptomatic, the mentioned option is not applicable in our case because the patient was in pain which is not relieved entirely only by pain killers. The canal obliteration is a problem and the prognosis of any of treatment plan could be poor, which will lead to

extraction of the tooth in case when it will be symptomatic like in our case which is diagnosed with apical periodontitis. The decision was not easy to take for a young female patient because the prognosis is vague. We should emphasize that those cases with obliterated canal(s) are not uncommon and any general practice or specialist could face such a challenge.

CONCLUSION

Treatment of tooth with canal calcification is a challenging condition. The prognosis of which the treatment plan is the most recommended requires a thorough review of case by case. Treatment of young female patient anterior tooth with this condition is not easy especially when there are limited options. But still should give a chance for non-extraction procedure as a primary solution to give chance and see (watchful waiting) for at least three to six month follow up. The most anticipated outcome of the examination of the current patient is to observe that there is no tooth mobility and no bone resorption after this period of follow-up. It is concluded that in the current case the treatment options are limited, challenging, and depend on the way and how to approach the patient, however, the prognosis remains uncertain and eventually occasionally unexpected.

Acknowledgment

I would like to acknowledge the patient sister Nor' Ashikin Binti Zulkefli for her cooperation and patience during surgical procedure and for the time and effort to attend the clinic for follow up and x- ray taking for the period of more than twelve years. As well as the assistance provided by the staffs from the radiology unit at the faculty of dentistry. I also extend my acknowledgment to the dental surgery assistant sister Mastura Binti Kamarzaman, Department of Oral Maxillofacial Surgery and Oral Diagnosis, Oral Surgery Unit Faculty of Dentistry International Islamic University Malaysia for her assistance during the surgical procedure and the follow up of the patient. The authors acknowledge the research project ID: SRCG20-012-0012 for the financial support.



Conflicts of Interest: There are no conflicts of interest.

REFERENCES

- Petti, S., Glendor, U., & Andersson, L. (2018). World traumatic dental injury prevalence and incidence, a meta-analysis—One billion living people have had traumatic dental injuries. *Dental traumatology*, *34*(2), 71-86. DOI: 10.1111/edt.12389.
- Bhanushali, P., Katge, F., Deshpande, S., Chimata, V. K., Shetty, S., & Pradhan, D. (2020). COVID-19: Changing trends and its impact on future of dentistry. *International journal of dentistry*, *2020*. doi: 10.1155/2020/8817424. PMID: 32565812; PMCID: PMC7260644.
- Glendor, U., & Andersson, L. (2007). Public health aspects of oral diseases and disorders: dental trauma. *Community oral health*. London: Quintessence, 203-14.
- Renapurkar, S. K., & Abubaker, O. (2018). Diagnosis and management of dentoalveolar injuries. In: Fonseca RJ, editor. *Oral and Maxillofacial Surgery*. 3rd ed. St Louis, MO: Elsevier.
- Tavares, W. L. F., Viana, A. C. D., de Carvalho Machado, V., Henriques, L. C. F., & Sobrinho, A. P. R. (2018). Guided endodontic access of calcified anterior teeth. *Journal of endodontics*, *44*(7), 1195-1199. doi: 10.1016/j.joen.2018.04.014. PMID: 29941111.
- Lara-Mendes, S. T. O., Barbosa, C. F. M., Santa-Rosa, C. C., & Machado, V. C. (2018). Guided Endodontic Access in Maxillary Molars Using Cone-beam Computed Tomography and Computer-aided Design/Computer-aided Manufacturing System: A Case Report. *J Endod*, *44*(5), 875-879. doi: 10.1016/j.joen.2018.02.009. Epub 2018 Mar 20. PMID: 29571910.
- Lam, R., Abbott, P., Lloyd, C., Lloyd, C., Kruger, E., & Tennant, M. (2008). Dental trauma in an Australian rural centre. *Dental Traumatology*, *24*(6), 663-670. doi: 10.1111/j.1600-9657.2008.00689.x. PMID: 19021660.
- Diangelis, A. J., Andreasen, J. O., Ebeleseder, K. A., Kenny, D. J., Trope, M., Sigurdsson, A., Andersson, L., Bourguignon, C., Flores, M. T., Hicks, M. L., Lenzi, A. R., Malmgren, B., Moule, A. J., Pohl, Y., & Tsukiboshi, M. (2012). International Association of Dental Traumatology. International Association of Dental Traumatology guidelines for the management of traumatic dental injuries: 1. Fractures and luxations of permanent teeth. *Dent Traumatol*, *28*(1), 2-12. doi: 10.1111/j.1600-9657.2011.01103.x.
- Day, P. F., Flores, M. T., O'Connell, A. C., Abbott, P. V., Tsilingaridis, G., Fouad, A. F., ... & Levin, L. (2020). International Association of Dental Traumatology guidelines for the management of traumatic dental injuries: 3. Injuries in the primary dentition. *Dental Traumatology*, *36*(4), 343-359. doi: 10.1111/edt.12576. PMID: 32458553.
- Vinagre, A., Castanheira, C., Messias, A., Palma, P. J., & Ramos, J. C. (2021). Management of pulp canal obliteration—Systematic review of case reports. *Medicina*, *57*(11), 1237. doi: 10.3390/medicina57111237. PMID: 34833455; PMCID: PMC8625069.

