

## Catheter with Implantable Chamber Results of 432 Cases

Khalil Ghebouli<sup>1,3\*</sup>, Hanene Djeghri<sup>2</sup>, Nadjib Mebarki<sup>1</sup>, Mehdi Belbekri<sup>3</sup>, Mohamed amine Kecir<sup>3</sup>, Amar Djender<sup>3</sup>, Abdelnacer Haddam<sup>3</sup>

<sup>1</sup>Department of Cardiovascular Thoracic Surgery and Organ Transplantation University Hospital Mustapha Algiers, Algeria

<sup>2</sup>Department of anesthesia university hospital Constantine, Algeria

<sup>3</sup>Department of thoracic surgery university hospital Constantine, Algeria

\*Corresponding Author: Khalil Ghebouli

| Received: 01.01.2024 | Accepted: 09.02.2024 | Published: 16.02.2024

**Abstract:** The implantable catheter port is a permanent central venous access device typically used for long-lasting injectable treatments such as chemotherapy. **Materials and Methods:** We report a retrospective study spread over 6 years to identify 432 patients who benefited from the placement of an implantable catheter port. Patients were followed during hospitalization and at discharge, one month, and one year later. **Results:** The average age is 67.9 years. There are 284 women and 148 men. The primary cancer requiring the installation of a chamber is essentially represented by cancer and bronchopulmonary cancers. The right internal jugular approach was the most frequently performed. Complications are mainly represented by infection and pneumothorax. **Discussion and Conclusion:** For prolonged treatments or treatments with aggressive drugs for the veins, a central venous access is preferable to the short peripheral catheter because the repetition of the punctures and the venous irritation of certain injectable drugs expose to pain, thrombosis or even necrosis, peripheral veins. The implantable catheter chamber allows direct access to a vessel to position the end of the catheter at the entrance to the heart, therefore rapid blood dilution. This makes it possible to inject drugs over the long term and/or whose venous tolerance is poor. It is a quick and easy technique with low morbidity.

**Keywords:** implantable port, chemotherapy, complications, cancer, drugs, thrombosis

**Citation:** Khalil Ghebouli *et al.* Catheter with Implantable Chamber Results of 432 Cases. Grn Int J Apl Med Sci, 2024 Jan-Feb 2(1): 22-26.

## INTRODUCTION

An implantable catheter port (ICP) is defined as a system placed directly under the skin; it is a sterile device allowing skin access to the catheter [1].

The introduction of these devices dates from the early 1980s following the need, for certain pathologies (cancers, blood diseases), to increase access to the central venous network while maintaining the catheter in place. The system is designed to remain in place for years after its installation.

In 2007, a summary of existing recommendations in hematology recalled the benefit of ICP and recommended tunnelled catheters in intensive access situations (allopoietic stem cell transplantation or induction of acute leukemia) [2].

In 2009, the recommendations of the European Society for Clinical Nutrition and Metabolism specify that for home parenteral nutrition for more than three months, the choice between tunnelled venous access and ICP

depends on several factors: the patient's choice, the experience of healthcare teams and frequency of use. Preference is given to ICPs in cases of intermittent vascular access and to tunnelled catheters for continuous use [3].

Implantable catheter ports (ICPs) have therefore increasingly become essential tools for the management of oncology patients, throughout the cancer disease, both for the administration of chemotherapy and for parenteral nutrition, transfusion, antibiotic therapy, pain treatment, repeated general anesthesia.

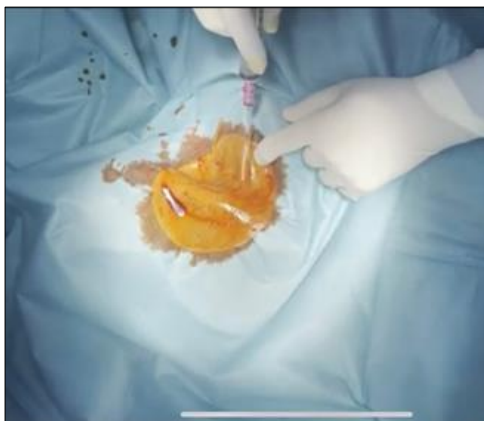ICP are therefore an essential tool for a substantial number of patients. Essential, but not without complications [4-6]. It therefore seemed important to evaluate our experience, in order to improve the technique and reduce morbidity, while specifying the indications for implantation.

## MATERIALS AND METHODS

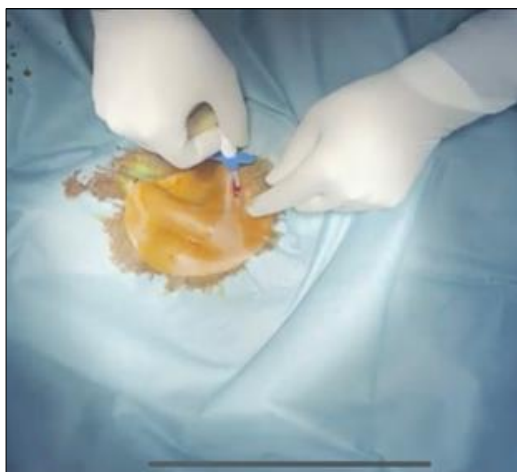
This is a retrospective study spanning a period of 6 years and involving 432 patients. The performance of the procedure was scheduled, the patients were transferred to our training from various departments and for each pose we established a sheet on which all the information was noted. All our patients were informed, explaining the indication and the equipment to use.

The installation can be performed under local or general anesthesia depending on the choice of the surgeon and the patient. The installation technique has been debated by several authors, analyzing the disadvantages and advantages of each of them.

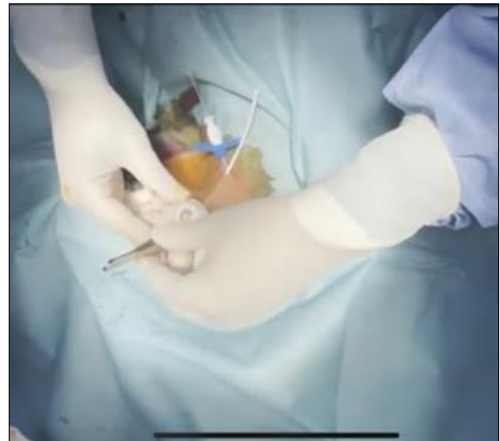
In our series we opted for the transcutaneous route by puncture of the subclavian vein or the internal jugular vein; the presence of venous blood reflux and good passage after injection were the criteria for the success of the implantation. The device is inserted into the subcutaneous space and attached to a muscular plane. The location of the box depends on the place of insertion of the catheter. Generally it is located under the clavicle and the catheter is introduced into a large vessel so that its distal end is located at the entrance to the right atrium, ideally in the superior vena cava (Figure 1,2,3,4).



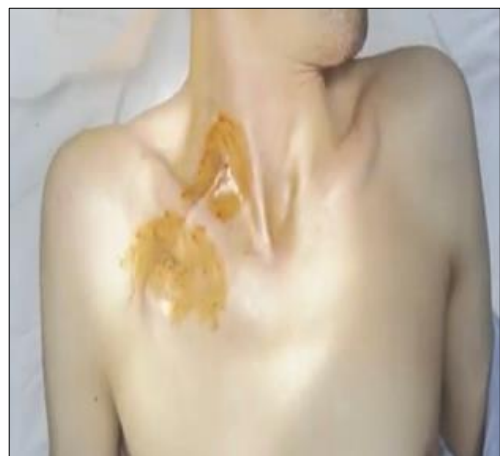**Figure 1 : placement of a central venous line**



**Figure 2: introduction of the dilator**

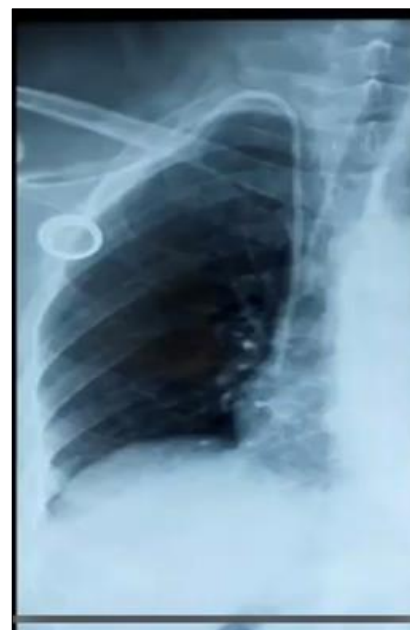

**Figure 3: tunneling and setting up the chamber**



**Figure 4: post-operative appearance**

An X-ray check in the operating room showing the location of the catheter and the chamber (Figure 5).



**Figure 5: control x-ray**

We did not use intraoperative antibiotic prophylaxis. All patients stayed for at least 24 hours except one patient who stayed 3 days. Patients were followed during hospitalization and discharge, one month later and one year.

**RESULTS**

This is a retrospective study of 432 patients admitted for placement of an implantable catheter port for chemotherapy. The average age is 67.9 years with

extremes ranging from 32 years to 81 years, These are 284 women and 148 men.

The primary cancer is represented by breast cancer in 168 cases or 38.98%, bronchopulmonary cancers come second in 126 cases (22.69%), followed by digestive cancers in 76 cases (17.59%), lymphomas and leukemia in 65 cases (15.05%), gynecological cancers in 15 cases or 3.47% and finally bone cancers in 10 cases (2.31%) (Table-1).

**Table 1: etiologies requiring the installation of an implantable port**

Etiologies:	Number n	Percentage %
Breast cancer	168	38.89%
Bronchopulmonary cancers	98	22.69%
Digestive Cancers	76	17.59%
Lymphomas and leukemias	65	15.05%
Gynecological cancers	15	3.47%
Bone cancers	10	2.31%
Total	432	100%

The implantable port was placed for all patients under local anesthesia in three cases it was associated with light sedation. For anatomical and technical reasons we have always preferred the right internal jugular

approach, in fact this right internal jugular route was performed in 352 cases, the left internal jugular vein was used in 50 cases, the right subclavian vein in 26 cases, and left subclavian in 4 cases (Table 2).

**Table 2: technique and side of installation**

Puncture route	Side	Number n	Percentage %
Internal jugular route	Right	352	81.84%
	Left	50	11.57%
Subclavian route	Right	26	6.02%
	Left	4	0.93%
Total		432	100%

The installation of an implantable port is a simple and quick technique which offers comfort to the patient but which is not without complications. In fact, in our series, complications occurred in 12 patients, a rate of 2.78%.

In our study we noted a case of hemothorax (0.23%), it was a moderately abundant hemothorax treated by chest drainage, the patient was kept under observation for three days, the evolution was favorable after drainage.

Infection of the surgical site generally observed one month to 6 months after placement of the chamber attested by the presence of pain at the surgical site and the observation on clinical examination of local signs of inflammation more rarely coming from pus. Was observed in 4 cases (0.93%) justifying the removal of the device and the initiation of antibiotic therapy.

Venous thromboses revealed by the presence of pain with edema of the arm were confirmed by performing a Doppler ultrasound were observed in 2 cases (0.46%) justifying the removal of the catheter with heparin therapy, no case of embolism pulmonary was not observed.

Pneumothorax was also observed in 4 cases (0.93%), diagnosed by the control chest X-ray, it was partial pneumothorax treated by simple bed rest.

Migration of the catheter by disconnection diagnosed by frontal radiography was observed in only one case (0.23%), this was a catheter placed via the right internal jugular route and which required its removal by endovascular route (Table-3).

**Table 3: complications linked to the installation of an implantable port**

Complication	Number n	Percentage %
Surgical site infection	4	0.93%
Pneumothorax	4	0.93%
Vein thrombosis	2	0.46%
Hemothorax	1	0.23%
Catheter migration	1	0.23%
Total	12	2.78%

## DISCUSSION

432 patients who benefited from ICP over a period of 6 years. The average age of our patients was 67.9 years; with extremes ranging from 32 years to 81 years. We note a female predominance; this is due to the recruitment of patients where breast cancer and gynecological cancers are the prerogative of the female sex.

The preference for the right side (378 cases) for us is made for anatomical reasons and the choice is also made according to local conditions, including certain contraindications we preferred the placement on the left side (prior irradiation, infection or anatomical anomaly), the finding described in most articles.

Infection represents the main complication occurring during the use of implantable catheter ports, present in our series in 0.93% of cases, this rate seems lower than that found in the literature which is of the order of 1.2% in the Paoli series [6], 2.7% in the Champault series [7], and 5.4% in the Goltz series [8]. The highest rate 8.8% was recorded in the Rouzrokh series [9].

The Pronovost study carried out in 2006 showed that 5 simple preventive measures (maximum aseptic barriers, hand washing, use of chlorhexidine, rapid removal of an unnecessary catheter and avoidance of the femoral route as far as possible) imposed in 103 American intensive care units reduced the incidence of catheter-related infections from 7.7 to 1.4 infections per 1000 catheter days [10].

Lefrant [11], found in a prospective series of 707 central venous catheters placed by surgical method, an incidence of pneumothorax of 3.1%, just like Lmakini [12], who also found an incidence of pneumothorax in his prospective series of 101 catheters by 3%.

In our work, the incidence of pneumothorax was 0.98%, this could be explained by the fact that we will favor the jugular route over the subclavian route; in fact, the frequency of pneumothorax varies according to the studies between 1.5 and 4% for the subclavian route and remains less than 1% for the internal jugular route. This frequency increases in subjects with atypical morphology (cachectic, obese, emphysematous) and decreases with the experience of the operator [11, 12].

It seems essential to remember that any failure of puncture (in particular of the subclavian vein) prohibits an attempt on the opposite side before a delay of several hours due to the risk of bilateral pneumothorax [13].

The incidence of thrombosis linked to CCI varies considerably between the different studies (differences in the type of CCI, the duration of the study, the inhomogeneous population, variable definition of symptomatic and non-symptomatic venous thrombosis, different diagnostic means depending on the studies). The incidence of ICC-related thrombosis appears to be

higher in older studies compared to more recent studies which may be explained by improvements in ICC insertion technique [14]. In our study it is around 0.46%.

Migration of the catheter by disconnection of the chamber and cases of obturation of the chamber with an implantable catheter has been described in the literature; its rate varies from 0% to 6.7% [7-9].

## CONCLUSION

CCIs have established themselves as essential tools in the management of patients receiving intravenous chemotherapy to ensure the different types of injection in complete safety and preserve venous capital. The CCI is installed before the start or after chemotherapy. The installation is done in the operating room by a surgeon, an intensivist or a radiologist.

The insertion of CCI meets criteria while involving few complications, likewise it is important to emphasize the importance of training medical and paramedical staff regarding the use of the room.

## REFERENCES

1. Agence nationale d'évaluation en santé (ANAES). Evaluation des pratiques professionnelles dans les établissements de santé - Evaluation de la qualité de l'utilisation et de la surveillance des chambres à cathéter implantables. Décembre 2000.
2. Bishop, L., Dougherty, L., Bodenham, A., Mansi, J., Crowe, P., Kibbler, C., ... & Treleaven, J. (2007). Guidelines on the insertion and management of central venous access devices in adults. *International journal of laboratory hematology*, 29(4), 261-278.
3. Pittiruti, M., Hamilton, H., Biffi, R., MacFie, J., & Pertkiewicz, M. (2009). ESPEN guidelines on parenteral nutrition: central venous catheters (access, care, diagnosis and therapy of complications). *Clinical nutrition*, 28(4), 365-377.
4. Sánchez, L. Y., Galbis Caravajal, J. M., Fuster Diana, C. A., & Eiras, E. M. (2006). Protocol for the implantation of a venous access device (Port-A-Cath System). The complications and solutions found in 560 cases. *Clinical and Translational Oncology*, 8, 735-741.
5. Dillon, P. A., & Foglia, R. P. (2006). Complications associated with an implantable vascular access device. *Journal of pediatric surgery*, 41(9), 1582-1587.
6. Paoli, C., Bassot, V., el-Bez, M., Corbin, M., Boissady, M. F., Trotoux, J., & Bonfils, P. (1994). Cervicofacial cancerology: complications of implantable systems of venous access. Prospective study. *Presse Medicale (Paris, France: 1983)*, 23(14), 649-652.
7. Champault, G. (1985). Completely implantable catheters for anticancer chemotherapy. A French

- experience of 325 cases. *Journal de Chirurgie*, 122(4), 269-272.
8. Goltz, J. P., Scholl, A., Ritter, C. O., Wittenberg, G., Hahn, D., & Kickuth, R. (2010). Peripherally placed totally implantable venous-access port systems of the forearm: clinical experience in 763 consecutive patients. *Cardiovascular and interventional radiology*, 33, 1159-1167.
  9. Rouzrokh, M., Shamsian, B. S., Khalegh, N., Tabari, A., Mahmoodi, M., & Kouranlo, J. (2009). Totally implantable subpectoral vs subcutaneous port systems in children with malignant diseases. *Arch Iran Med*, 12(4), 389-394.