

## Vaginal Agenesis: Diagnosis on Ultrasound and Management of a Case at the Gabriel Toure University Hospital in Bamako (Mali)

Sylla Cheickna<sup>1,4</sup>, Fané Seydou<sup>1,4</sup>, Bocoum Amadou<sup>1,4</sup>, Simpara Nouhoum<sup>2,5</sup>, Koné Sidi Bocary<sup>3,4</sup>, Siaka Amara Sanogo<sup>1,4</sup>, Dembele Sitapha<sup>6</sup>, Dembélé Yacouba<sup>7</sup>, Teguete I<sup>1,4</sup>, Traoré Youssouf<sup>1,4</sup>, Mounkoro Niani<sup>1,4</sup>

<sup>1</sup>Department of Obstetrics and Gynecology, Gabriel Touré University Hospital, Bamako, Mali

<sup>2</sup>Referral Health Centre of Commune VI of Bamako, Mali

<sup>3</sup>Department of Obstetrics and Gynecology, Mohamed VI Polyclinic, Bamako, Mali

<sup>4</sup>Obstetrician-gynecologist with a university degree in gynecological and obstetric ultrasound

<sup>5</sup>Specialist in medical imaging and diagnostic radiology

<sup>6</sup>Department of Obstetrics and Gynecology, Fousseyni DAO Hospital, Kayes, Mali

<sup>7</sup>Kadiolo Referral Health Centre, Sikasso, Mali

\*Corresponding Author: Dr. Sylla Cheickna

| Received: 25.12.2024 | Accepted: 11.02.2024 | Published: 04.03.2024

**Abstract:** Vaginal malformations can be diagnosed by ultrasound in a large number of cases. The prevalence of uterovaginal aplasia usually reported in the literature is 1/4000 to 1/10,000. **Objectives:** We tell you about the difficulties of diagnosis with ultrasound, the difficulties of managing our case of vaginal aplasia. **Observation:** This was a 20-year-old patient saleswoman, single. **History of the Disease:** was marked by cyclic pelvic headache for 6 months with primary amenorrhea. She has no particular medical-surgical history. **On Physical Examination:** secondary sexual characteristics were developed. On inspection of the vulva, normal pubic hair was noted. Examination of the vulva showed the labia majora and labia minora present and normal-looking. A hymen could not be identified and there was no visible vaginal opening. Faced with this clinical and paraclinical symptomatology, we made the diagnosis of vaginal agenesis. The ultrasound showed a uterus measuring about 92x71x62 mm, its parenchyma is homogeneous, its contours are regular. The presence in the uterine cavity at the corporeofundic level of a homogeneous echogenic collection of about 66.5 cc (69x35 mm). Note the congenital malformation of the cervix with agenesis). **The Surgical Procedure Performed:** is vaginoplasty. **Conclusion:** Ultrasound of uterine malformation is difficult and requires some experience from the sonographer.

**Keywords:** ultrasound, uterovaginal agenesis, vaginoplasty

**Citation:** Sylla Cheickna *et al.* Vaginal Agenesis: Diagnosis on Ultrasound and Management of a Case at the Gabriel Toure University Hospital in Bamako (Mali). Grn Int J Apl Med Sci, 2024 Mar-Apr 2(2): 27-33.

## INTRODUCTION

Present in about 0.5% of cases, sometimes unnoticed or incidentally discovered, vaginal malformations are sought after due to fertility disorders, miscarriages or menstrual abnormalities. These uterovaginal malformations can be diagnosed by ultrasound in a large number of cases. All of these abnormalities result from a halt or defect in the development and fusion of the Müllerian ducts, which are responsible for the formation of the upper two-thirds of the vagina, cervix, and uterus [1]. Mayer-Rokitansky-Küster-Hauser syndrome (MRKH) or uterovaginal aplasia or Mullerian aplasia is a congenital malformation characterized by the complete absence of uterus and the upper two-thirds of the vagina, a female phenotype, and a karyotype 46, XX. One of the main goals of therapeutic management is to treat vaginal aplasia and optimize the onset of

sexuality [1]. The management of vaginal aplasia can be either non-surgical, with the Frank method, which consists of progressive vaginal dilation through the use of candles, or surgical with different techniques described.

Comparative studies on the use of different methods conclude that treatment with vaginal dilation should be indicated as a first-line treatment in the treatment of vaginal aplasia in patients with MRKH syndrome. Indeed, the superiority of Frank's method over surgery has been demonstrated in terms of anatomical results and overall or sexual quality of life. In addition, surgery, regardless of the technique used, is associated with more immediate and long-term complications. Unlike surgical techniques for which there is a description of regulated techniques, the vaginal dilation method is less protocolized. Thus, recommendations on

the frequency and duration of dilations vary widely. The prevalence of vaginal aplasia usually reported in the literature is 1/4000 to 1/10,000. The most recent epidemiological study indicates a frequency of 1/5,000 female births [1]. This abnormality accounts for 85% of vaginal aplasia and is the second leading cause of primary amenorrhea after gonadal dysgenesis. In Mali, we did not find any scientific studies in the literature on uterovaginal aplasia. We report to you the difficulties of diagnosis with ultrasound, the difficulties of management for the diagnosis of our case of vaginal aplasia.

### OBJECTIVES

The aim **wasto** describe the contribution of ultrasound in the diagnosis of vaginal aplasia and to write the clinical and management aspects.

### CASE OBSERVATION

**Characteristics of the Patient:** She was a 20-year-old patient saleswoman, single residing in Yanfolila (Sikasso Region).

### History of the Disease

The onset of the symptomatology would date back to this day 11/01/2023 marked by intense abdominopelvic pain in a context of primary amenorrhea without any other associated sign. In front of which the parents brought him to the community health center of Yanfolila (3rd Region) who referred him to us for hematometry with congenital absence of the cervix. It indicates a notion of cyclical pelvic pain (at the end of each month) for about 6 months. She has no particular medical-surgical history.

### On Physical Examination

She was in good general condition, conjunctiva colored, consciousness good, breasts were anodular symmetrical pairs (developed secondary sexual characteristics).

Blood pressure: 120/70mm, Temperature 37.1°C, pulse rate at 86beats per minute. The abdomen was supple, depressible with no palpable mass in the pelvic area. On inspection of the vulva, normal pubic hair was noted. Examination of the vulva showed the labia majora and labia minora present and normal-looking. A hymen could not be identified and there was no visible vaginal opening. Faced with this clinical and paraclinical symptomatology, we made the diagnosis of vaginal agenesis.

### The Result of the Biological Assessment

Rhesus grouping: O+S Positive. Complete blood count: Hemoglobin level: 18.66g/dl and hematocrit level: 56%. Prothrombin level: 89%. Activated partial thrombosis time: patient 31s. Blood glucose: 3.45mmol/L. Creatinine levels: 110mol/L. INR 1.13.

### Theultrasound Scans Performed

#### The Report of the First Ultrasound (Figure 3)

It was performed by a logic 500 device equipped with a 3.5MHZ convex probe and a 7.5MHZ linear probe. We performed transparietal first axial sections of the intra-abdominal organs which show us a liver is of normal size, measuring 13.3cm of hepatic arrow. Its contours are regular and its ultrasound is homogeneous without focal lesions. The gallbladder is in semi-repletion, its content anechoic and its wall thin. The kidneys are well differentiated, alithiasic and normal in structure. The spleen and pancreas are without ultrasound abnormalities. No ascites or deep abdominal lymphadenopathy. The uterus is enlarged in size measuring more than 93 x 57 x 87mm. Its contours are regular and its echostructure is homogeneous containing a cloudy effusion of medium abundance. The ovaries are of normal size and morphology. The bladder is anechoic in content and thin-walled. Diffuse colonic airy distension.

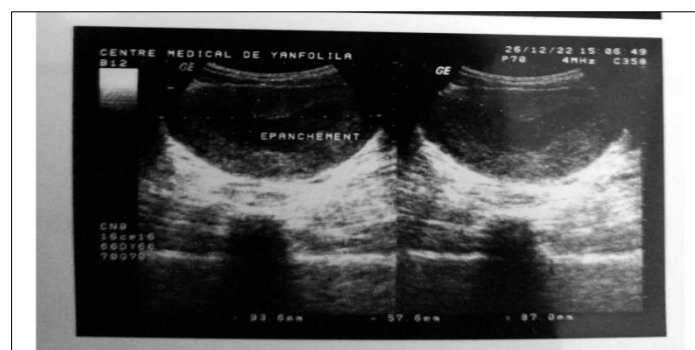

Figure 1: Cross-Section of the Suprapubic Uterus Showing an Anechoic Image in the Uterus (Collection).

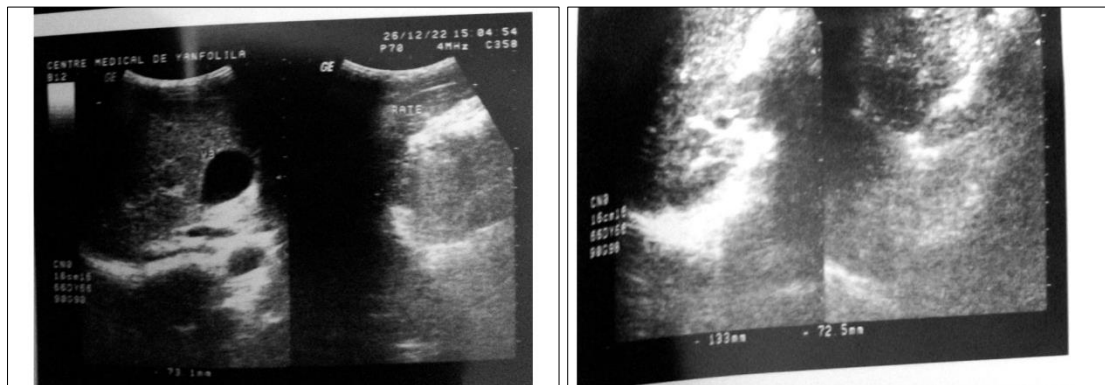
### The Report of the Second Ultrasound (Figure 4)

The examination is performed by an APOGEE 800 device with pulsed and continuous color Doppler equipped with a 3.5MHZ probe and an endovaginal probe. *The different cutting planes allowed us to highlight. On an axial section above the pubic area, the bladder: seen in semi-repletion is alithiasis, non-tumor*

thin-walled with anechoic contents. a uterus: in the anteflexed, anteverted position, measures: 99x75x68mm, its contours are regular and its parenchyma is homogeneous with the presence of an anechoic fluid effusion (haematometry) in the endocavity. The right ovary is the seat of a dual tissue

and cystic formation measuring 64x41mm. The left

ovary measures: 30x19mm. The Douglas was free.



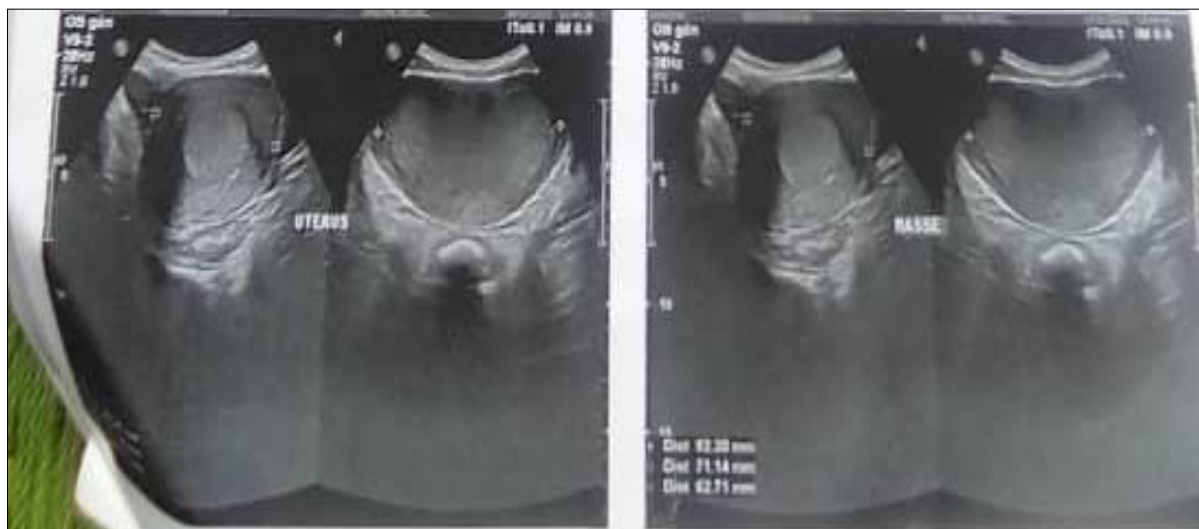**Figure 2: Abdominopelvic Ultrasound.**

**The Report of the Third Ultrasound (Figures 5, 6 and 7).**

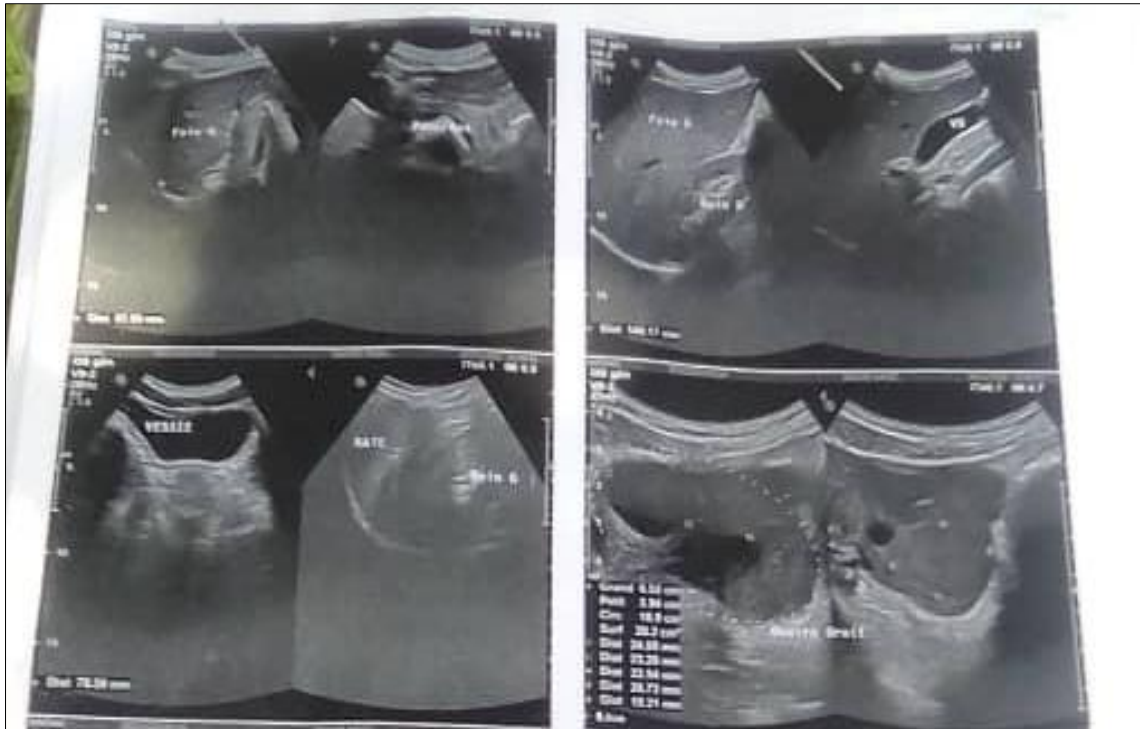
The examination is performed in real time on a PHILIPS AFFINITY SOW device with Color Doppler equipped with a 3.5 Mhz convex probe; a 7.5 MHz linear probe and an endovaginal probe.

*The different cutting planes allowed us to highlight. On an axial cross-section, trans-abdominal approach, the liver measures 146 mm on the mid-clavicular line and 97 mm anterior to the aorta. Its contours are regular and its parenchyma homogeneous. The hepatic vessels (portal trunk and veins above the liver) are permeable and of normal size. The gallbladder is in an ordinary position, of normal shape, of unremarkable size. Its contents are anechoic, without stones. It has a thin wall. No dilation of the intra- and/or extra-hepatic bile ducts. The pancreas appears homogeneous and not enlarged in size. The Wirsung is not dilated. The spleen measures 78 mm long axis, it is homogeneous and its contours are regular. The kidneys are in an anatomical position, their contours are regular. They have good parenchymo-*

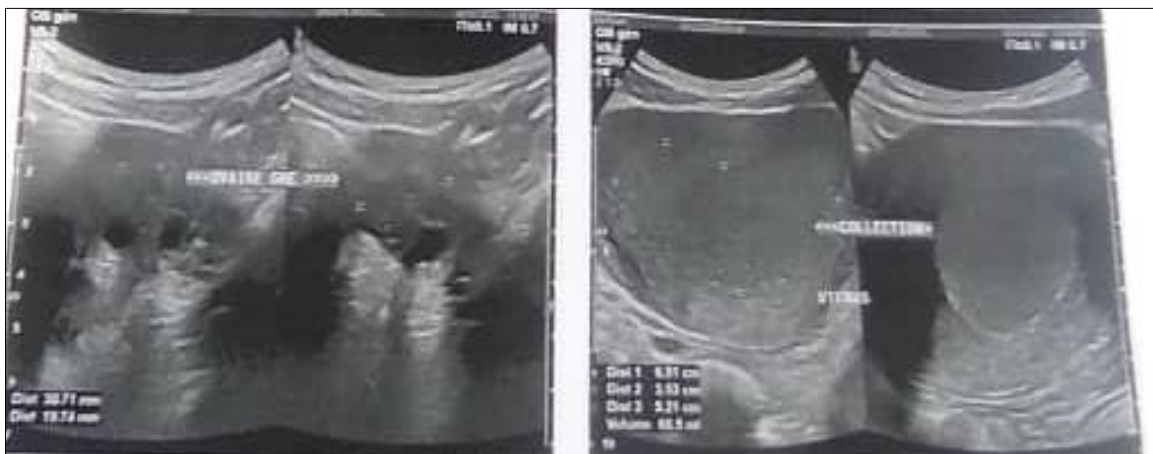
*central differentiation. They are alithiasis, no dilation of the pyelo-calicial and/or ureteral cavities. The parenchyma are of normal thickness. The adrenal lodges are free. The semi-repleted bladder is transsonant, alithiasic and thin-walled. No ascites or deep lymphadenopathy. The handles are endowed with good peristaltic movement. On axial and sagittal sections above the pubic area, we have a uterus measuring about 92x71x62 mm, its parenchyma is homogeneous, its contours are regular. Presence in the uterine cavity at the corporeofundic level of a homogeneous echogenic collection of about 66.5 cc (69x35 mm). It should be noted that the cervix could not be clearly distinguished today (congenital malformation of the cervix with agenesis?). The endometrium could not be studied from the collection described above. The left ovary is visualized. It has no abnormalities in dimensions or echostructure. The right ovary is dystrophic (65x39 mm or about 20 cm<sup>2</sup>) with a thick-walled cystic formation contained in 26x15 mm ground glass. No vegetation or solid portion within the cyst. The Douglas is free.*



**Figure 3: Ultrasound Images (Sagittal And Axial Sections of the Uterus Showing a Thickened Endometrium, Absence of Isthmic Image, Absence of Cervix And Vaginal Canal).**



**Figure 4: Axial Sections of the Liver, Kidneys, and Bladder through the Pubic Route**



**Figure 5: Abdominopelvic Ultrasound Showing the Liver, Kidneys (Looking For Other Malformations).**

**Practical Pipe:** The announcement of the anomaly: detailed explanation of the malformation.

### Surgical Technique

#### 1st Step

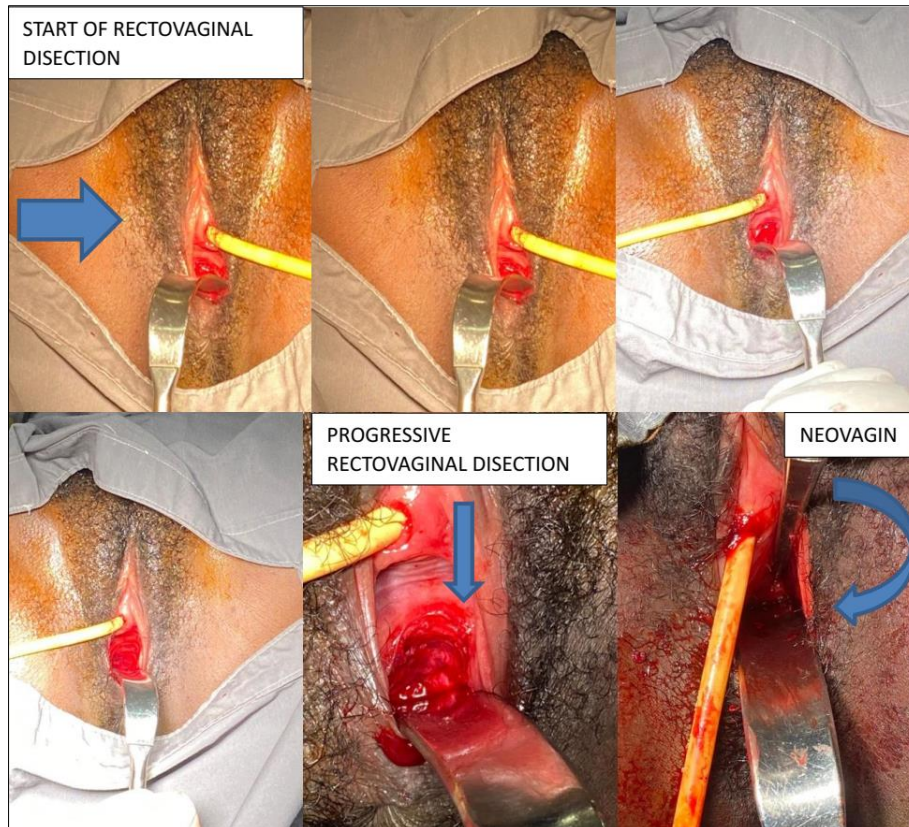
The procedure consisted of an incision over 1cm in width and a dissection over 3cm in depth towards the vaginal cavity. This maneuver did not result in a vaginal cavity to allow the hematocolpos. In the face of

a 3 cm dissection, we ruled out the diagnosis of hymeneal imperforation.

#### 2nd Step

This stage consisted of a 7cm vesico-rectal detachment. This did not allow a cervix to be seen. We decided to stop the procedure at this level to better prepare the patient. This vesico-rectal detachment created a 7cm neovagina.





**Figure 6: Appearance before the Operation and the Different Stages of the Procedure: Vesico-Rectal Detachment with the Creation of the 7cm Neovagina (6 Photos Gabriel Touré University Hospital, Bamako, Mali).**

### Post-Operative Care

Psychotherapy was performed. The drugs prescribed were amoxicillin 500mg, diclofenac suppository, gynecological betadine. Ultrasound is operator-dependent. Such an abnormality is difficult to diagnose even in a trained hand. However, the clinical context of primary amenorrhea should be investigated for malformative abnormalities of the genital tract.

### Postoperative Follow-Up

An appointment is given within three months for follow-up and in order to do an upper intervention combined with the vaginal route to evacuate the hematometry, make an opening of the uterus in the artificial vagina created in order to avoid a new collection of menstruation in the uterus.

### Anatomical and Functional Results

We did not note any psychological trauma related to the announcement of the malformation, nor during treatment. The length of the neovagina assessed at two weeks postoperatively was 7cm. The follow-up of the neovagina to assess the anatomical results we obtained, was satisfactory in the first two weeks.

## DISCUSSION

In the literature, medical imaging occupies a secondary place in the diagnosis of vaginal aplasia. Pelvic ultrasound provides an image of a haematometry with total or partial vaginal agenesis, functional ovaries

containing follicles. Renal ultrasound or intravenous urography will look for an associated urinary malformation [30]. In our study, we found a haematometry (presence in the uterine cavity at the corporefundic level of a homogeneous echogenic collection of about 66.5 cc (69x35 mm). The cervix could not be clearly distinguished: congenital malformation of the cervix with agenesis. The endometrium could not be studied from the collection described above. The left ovary is visualized. It has no abnormalities in dimensions or echostructure. The right ovary is dystrophic (65x39 mm or about 20 cm<sup>2</sup>) with a thick-walled cystic formation contained in 26x15 mm ground glass. Indeed, the early recognition of a pelvic kidney, especially a single one, will avoid possible trauma during surgical reconstruction. The interest of MRI is to better specify the height and extent of vaginal aplasia, thus making it possible to guide the choice of the most appropriate surgical technique [33]. Several surgical techniques have been described in the literature to treat vaginal agenesis. The first, Frank's method, is non-surgical. The most widely used surgical techniques are those of Vecchietti and McIndoe. We used surgical lengthening using the technique of elective vaginal cup vaginoplasty. The anatomical and functional results we obtained were satisfactory. Frank's method involves a gradual increase in the size of the dilators [7]. The Vecchietti technique, a laparotomy surgical variant of Frank's, involves the implantation of a device that increases the depth of the vaginal cup [11]. This

technique does not require vesicorectal dissection. McIndoe's technique uses thin skin grafting into the surgical space created between the bladder and rectum and held in place by a stent [12, 13]. Most surgical techniques involve a first stage of intervesico-rectal cleavage by the vaginal route, by the combined abdominoperineal route or by the upper route only, and a second time of recovery of this cleavage. Recovery can be done by spontaneous epithelialization on a mold, grafting of ovular membranes [14], protective films [13], splitting of the labia minora [15], skin expansion, skin grafting [16], skin flaps or pelvic peritoneum grafting [13]. The feasibility of the laparoscopic route has been demonstrated by isolated cases, by Ikuma *et al.*, [17], Darai *et al.*, [18], Ota *et al.*, [19], and Thoury *et al.*, [20]. As a result, few data exist regarding anatomical and functional outcomes. All vaginoplasty techniques have advantages and disadvantages and it is futile to claim that one is superior to the others. There is no consensus on surgical correction [21]. Frank's method has the advantage of avoiding surgery. It requires long periods of dilation, so the patient's cooperation is paramount. The Vecchietti technique has the highest rate of urinary complications (2.1%), compared to other procedures [22]. Similarly, daily vaginal dilation is necessary before the onset of intercourse and when the depth of the neovagina is limited [23]. In case of failure, procedures requiring the wearing of a mandrel or the practice of instrumental dilations may be proposed to cooperative and determined patients, striving to avoid the long and tedious consequences of spontaneous epithelialization on a mold. The advantages of McIndoe's technique are the simplicity of the surgical procedure and the absence of intestinal complications. On the other hand, the main disadvantages are the lack of vaginal lubrication, the need for long dilation and the wearing of stents during the night. In addition, there is a high risk of narrowing, dyspareunia, and stenosis [24]. More risky procedures will be considered in patients who want an immediate result. The implementation of similar treatments must be accompanied by psychological support. Sigmoid transplantation provides adequate vaginal length, natural lubrication, and early sex in four to six weeks. The sigmoid grafting technique is associated with a low risk of vaginal opening stenosis unless there is excessive traction on the sigmoid transplant; Similarly, the risk of shortening the length of the transplant is minimal [25]. Martinez-Mora *et al.*, [26], have shown that sigmoid colpoplasty gives the best short- and long-term results with minimal prevalence of transplant prolapse [27]. The vulva keeps a normal appearance. However, this method involves a major laparotomy that is not exempt from the usual risks of digestive surgery including colonic and rectal perforation in 1 and 3% respectively [28]. Similarly, there is a risk of bowel obstruction inherent in any laparotomy. Nowadays, the prognosis is that of a colocolonic suture without shunt or drainage, on a healthy, well-vascularized and young colon.

There is little literature on laparoscopic and perineal sigmoid colpoplasty [7-19]. The anatomical results are encouraging, consistent with the results of Darai's 2003 publication [29], and studies of sigmoid colpoplasty by laparotomy [25, 26]. On the psychological level, we did not note a nervous breakdown.

**Limitations of the Study:** We had difficulties in doing a long-term post-operative follow-up that allows us to properly assess the functionality of the neovagina.

## CONCLUSION

Ultrasound of uterine malformation is difficult and requires some experience from the sonographer. In the presence of clinical symptoms suggestive of a uterine malformation (primary amenorrhea with cyclic pelvic headache), the ultrasound should be performed by a referring sonographer to optimize the result obtained.

## BIBLIOGRAPHIES

1. Louis-Sylvestre, C., Cheikhelard, A., Pelet, A., Crétolle, C., Gernet, I., & Polak, M. (2011). Uterovaginal aplasia. *EMC – Gynecology*, 6(4), 113.
2. Cheikhelard, A., Bidet, M., Baptiste, A., Viaud, M., Fagot, C., Khen-Dunlop, N., ... & Pienkowski, C. (2018). Surgery is not superior to dilation for the management of vaginal agenesis in Mayer-Rokitansky-Küster-Hauser syndrome: a multicenter comparative observational study in 131 patients. *American journal of obstetrics and gynecology*, 219(3), 281-e1.
3. Willemsen, W. N., & Kluivers, K. B. (2015). Long-term results of vaginal construction with the use of Frank dilation and a peritoneal graft (Davydov procedure) in patients with Mayer-Rokitansky-Küster syndrome. *Fertility and sterility*, 103(1), 220-227.
4. Hauser, G. A., Keller, M., & Koller, T. (1961). "Das Rokitansky-Küster-Syndrom. Uterus bipartus solidus rudimentarius vagina solida, *Gynaecologia, Basel*, 151, 111-112.
5. Mayer, C. A. J. (1829). Über Verdoppelungen des uterus und ihre arten, nebst Bemerkungen über Hasenscharte und Wolfsrachen. *J Chir Auger*, 13, 525-564.
6. Guerrier, D., Mouchel, T., Pasquier, L., & Pellerin, I. (2006). The Mayer-Rokitansky-Küster-Hauser syndrome (congenital absence of uterus and vagina)–phenotypic manifestations and genetic approaches. *Journal of negative results in biomedicine*, 5, 1-8.
7. Cai, B., Zhang, J. R., Xi, X. W., Yan, Q., & Wan, X. P. (2007). Laparoscopically assisted sigmoid colon vaginoplasty in women with Mayer-Rokitansky-Küster-Hauser syndrome: Feasibility and short-term results. *BJOG: An International Journal of Obstetrics & Gynaecology*, 114(12), 1486-1492.

8. Reinhold, C., Hricak, H., Forstner, R., Ascher, S. M., Bret, P. M., Meyer, W. R., & Semelka, R. C. (1997). Primary amenorrhea: evaluation with MR imaging. *Radiology*, 203(2), 383-390.
9. Kuttann, F., WRIGHT, F., Spritzer, P., Mowszowicz, I., & Mauvais-Jarvis, P. (1987). Les syndromes d'insensibilité aux androgènes. In *Annales d'urologie* (Vol. 21, No. 4, pp. 227-234).
10. Kolon, T. F., Gray, C. L., & Borboroglu, P. G. (1999). Prenatal karyotype and ultrasound discordance in intersex conditions. *Urology*, 54(6), 1097.
11. Vecchiotti, G. (1965). Creation of an artificial vagina in Rokitansky-Küster-Hauser syndrome. *Attualità di ostetricia e ginecologia*, 11(2), 131-147.
12. Creatsas, G., Deligeoroglou, E., Makrakis, E., Kontoravdis, A., & Papadimitriou, L. (2001). Creation of a neovagina following Williams vaginoplasty and the Creatsas modification in 111 patients with Mayer-Rokitansky-Küster-Hauser syndrome. *Fertility and sterility*, 76(5), 1036-1040.
13. Davydov, S. N. (1969). Colpopoiesis from the peritoneum of the uterorectal space. *Obstet Gynecol*, 12, 55-7.
14. Brindeau, A., Lantuejoul, P., & Hubert, L. (1946). Creation of an artificial vagina using the ovular membranes of a full-term egg. *Gynecol Obstet*, 45, 417-42.
15. Tescher, M., & Remay, Y. (1977). Epithelialization of a neovagina by nymphoplasty. *New Med Press*, 6, 4063-4.
16. McIndoe, A. H., & Banister, J. B. (1938). An operation for the cure of congenital absence of the vagina. *BJOG: An International Journal of Obstetrics & Gynaecology*, 45(3), 490-494.
17. Ikuma, K., Ohashi, S., Koyasu, Y., Tei, K., & Haque, S. M. (1997). Laparoscopic colpopoiesis using sigmoid colon. *Surgical Laparoscopy Endoscopy & Percutaneous Techniques*, 7(1), 60-62.
18. Darai, E., Soriano, D., Thoury, A., & Bouillot, J. L. (2002). Neovagina construction by combined laparoscopic-perineal sigmoid colpoplasty in a patient with Rokitansky syndrome. *The Journal of the American Association of Gynecologic Laparoscopists*, 9(2), 204-208.
19. Ota, H., Tanaka, J. I., Murakami, M., Murata, M., Fukuda, J., Tanaka, T., ... & Koyama, K. (2000). Laparoscopy-assisted Ruge procedure for the creation of a neovagina in a patient with Mayer-Rokitansky-Küster-Hauser syndrome.
20. Thoury, A., Detchev, R., & Darai, E. (2002). Sigmoid neovagina by combined laparoscopic-perineal route for Rokitansky syndrome. *Gynecologie, Obstetrique & Fertilite*, 30(12), 938-943.
21. Laufer, M. R. (2002). Congenital absence of the vagina: in search of the perfect solution. When, and by what technique, should a vagina be created?. *Current Opinion in Obstetrics and Gynecology*, 14(5), 441-444.
22. McQuillan, S. K., & Grover, S. R. (2014). Dilation and surgical management in vaginal agenesis: a systematic review. *International urogynecology journal*, 25, 299-311.
23. Fedele, L., Bianchi, S., Zanconato, G., & Raffaelli, R. (2000). Laparoscopic creation of a neovagina in patients with Rokitansky syndrome: analysis of 52 cases. *Fertility and sterility*, 74(2), 384-389.
24. Buss, J. G., & Lee, R. A. (1989). McIndoe procedure for vaginal agenesis: results and complications. *Mayo Clin Proc*, 64, 758-61.
25. DelRossi, C., Attanasio, A., Domenichelli, V., & De Castro, R. (1999). Treatment of the Mayer-Rokitansky-Küster-Hauser syndrome in Bangladesh: results of 10 total vaginal replacements with sigmoid colon at a missionary hospital. *J Urol*, 162, 1138-40.
26. Martinez-Mora, J., Isnard, R., Castellvi, A., & Ortiz, P. L. (1992). Neovagina in vaginal agenesis: surgical methods and long-term results. *Journal of pediatric surgery*, 27(1), 10-14.
27. Yokomizo, R., Murakami, T., Naitou, H., & Yamada, A. (2002). Treatment for prolapse of the sigmoid neovagina in Mayer-Rokitansky-Küster-Hauser syndrome. *Obstetrics & Gynecology*, 100(5), 1085-1087.
28. Hendren, W. H., & Atala, A. (1994). Use of bowel for vaginal reconstruction. *The Journal of urology*, 152(2), 752-755.
29. Darai, E., Toullalan, O., Besse, O., Potiron, L., & Delga, P. (2003). Anatomic and functional results of laparoscopic-perineal neovagina construction by sigmoid colpoplasty in women with Rokitansky's syndrome. *Human Reproduction*, 18(11), 2454-2459.
30. Gilles, G., & Maitrot-Mantelet, L. (2022). *Practical Guide to Obstetric and Gynecological Ultrasound 3rd Edition* Elsevier Masson, 392 pages.
31. Camille Baraud. Management of vaginal aplasia in patients with MRKH (Mayer Rokitansky Küster Hauser) by the Frank method: duration of treatment required. *Human Medicine and Pathology*. 2019. FFDUMAS-03129075F.
32. Meklaa, A., Driss Rahali, M., & Mohammed, D. Vaginal aplasia with functional uterus: About a case. *Department of Gynaecology and Obstetrics*, Mohamed V Military Training Hospital in Rabat.