

Research Article

DOI: 10.62046/gijams.2024.v02i06.002

Effectiveness and side effects associated with Doxycycline as sclerotherapy in pediatric head and neck lymphangiomas

Tawfiqur Rahman¹, Masroor Rahman¹, Mohammad Anwar Hossain¹, Arif Mahmud Jewel¹, Abdullah-Al-Mamun¹, A. K. Al Miraj²

¹Assistant Professor, Department of Otolaryngology-Head & Neck Surgery, Bangabandhu Sheikh Mujib Medical University, Dhaka, Bangladesh

²Research Assistant, Department of Vascular Surgery, Bangabandhu Sheikh Mujib Medical University, Dhaka, Bangladesh

*Corresponding Author: Tawfiqur Rahman | Received: 28.09.2024 | Accepted: 22.10.2024 | Published: 12.11.2024

Abstract: **Introduction:** Common side effects of doxycycline include diarrhoea, itch and skin sensitivity. Doxycycline makes your skin more sensitive, so it's extra important to protect your skin from the sun, if you are taking it. Lymphangiomas are the congenital malformations of the lymphatic system which are benign in nature. They are classified as microcystic (capillary lymphangiomas), macrocystic (cavernous lymphangiomas) and cystic hygromas. **Objective:** To assess the effectiveness of intralesional Doxycycline sclerotherapy in pediatric head and neck lymphangioma. **Methods:** This was a retrospective review of chart of all children who underwent Doxycycline sclerotherapy for lymphangiomas of head and neck region in six months duration between January to June 2023. A total of 50 cases were treated with intralesional doxycycline. Medical records were reviewed and evaluated for following variables like age, sex, history, examination findings including site of lesion, ultrasonographic findings, number of injection, dose of Doxycycline and any side effects noted and the final outcome of sclerotherapy. **Results:** There was complete resolution of the macrocystic lesion in four cases (12.0%) after two sessions of Doxycycline sclerotherapy. The partial resolution of lymphangioma occurred in 31 cases (62.0%) with mixed type of lymphangioma whereas, in 13 cases (26.0%), there was no response observed even after six sessions of sclerotherapy. Minor side effects like local site erythema and swelling were observed in 31 cases. Secondary infection was seen in 13 cases. Six patients developed fever after injection which was resolved within 24 hours. **Conclusion:** Doxycycline sclerotherapy is safe and effective in the treatment of head and neck lymphangioma in the pediatric population. DS has distinct advantages over other sclerotherapy agents including that it is inexpensive and widely available, and has minimal side effects.

Keywords: Doxycycline, Lymphangioma, Pediatric, Sclerotherapy.

Citation: Tawfiqur Rahman *et al.* Effectiveness and side effects associated with Doxycycline as sclerotherapy in pediatric head and neck lymphangiomas. Grn Int J Apl Med Sci, 2024 Nov-Dec 2(6): 226-230.

INTRODUCTION

Common side effects of doxycycline include diarrhoea, itch and skin sensitivity. Doxycycline makes your skin more sensitive, so it's extra important to protect your skin from the sun, if you are taking it. Lymphangiomas are the congenital malformations of the lymphatic system which are benign in nature.[1] They are classified as microcystic (capillary lymphangiomas), macrocystic (cavernous lymphangiomas) and cystic hygromas.[2] Due to their location in the head and neck, they can cause a significant functional and cosmetic morbidity. Multiple studies have shown the effectiveness and excellent safety profile of doxycycline as a sclerosant used in sclerotherapy, [3] potential complications from doxycycline sclerotherapy typically include pain, fever, infection, and skin irritation. [4] Sclerotherapy with use of doxycycline after drainage is also advantageous because of its ease

of use. A single treatment dose is administered in our recovery area after any remaining fluid is evacuated from the lymphocele. Approximately 1 hour later, the sclerosing agent and catheter are removed. In children, these lesions may present with asymptomatic neck swelling with cosmetic deformity, recurrent infections, dysphagia, sleep disordered breathing, respiratory distress, etc. Lymphangiomas can be treated surgically or with a non surgical approach such as sclerotherapy. Numerous sclerosing agents have been described in the literature such as OK-432 (Picibanil), Bleomycin, Dextrose, ethanol, alcoholic solution of zein (Ethibloc), fibrin sealant (Tissucol), acetic acid and Doxycycline. [5-10] Doxycycline is a broad-spectrum antibiotic which is widely available and relatively inexpensive. Initial study by Molitch *et al.* demonstrated Doxycycline to be very efficient in decreasing the size of lymphangioma. [8] Doxycycline can cause certain

side effects (also known as adverse effects), some of which are more common than others. These side effects may be temporary, lasting a few days to weeks. However, if the side effects last longer than that, bother you, or become severe, be sure to talk with your doctor or pharmacist. Doxycycline has been shown to be effective with macrocystic and mixed lymphatic malformations of the head and neck in children. The exact mechanism of action of Doxycycline is unknown but it is speculated that an inflammatory process causes fibrosis and involution of cysts. [11] It is thought to inhibit matrix metalloproteinases and the vascular endothelial growth factor induced angiogenesis and lymphangiogenesis [12, 13].

MATERIALS AND METHODS

This was a retrospective review of chart of all children who underwent doxycycline sclerotherapy for lymphangiomas of head and neck region in six months duration between January to June 2023. A total of 50 cases were treated with intralesional doxycycline. Patients who underwent sclerotherapy with other sclerosants were excluded from this study. The medical records were reviewed and data were evaluated for the variables like; age, sex, history, examination findings including site of lesion, ultrasonographic findings, number of injections, dose of Doxycycline, side effects, and outcome of procedure. The lymphangiomas were classified as macrocystic lesions (cystic spaces $\geq 2 \text{ cm}^3$), microcystic lesions (cystic

spaces $< 2 \text{ cm}^3$), and mixed (both macrocystic and microcystic components).[8] The children had basic hematological investigation to rule out any bleeding and coagulopathy disorders. Doxycycline solution at a concentration of 10 mg/ ml was prepared by mixing 100 mg of Doxycycline powder with 10 ml of sterile distilled water. Under aseptic condition, intralesional Doxycycline 10mg /ml was injected at multiple sites after aspiration of lymphangioma fluid. We used a dose of 100 mg–800mg per session, depending on the age and weight of the child and the size of lesion. Doxycycline was injected under intravenous anaesthesia for children less than five years and under local anaesthesia for older children. Post procedure, the children were given analgesics for pain and observed for 24 hours in the hospital for any adverse reactions related to the procedure. The children were reassessed after six weeks and ultrasonography was repeated to assess the size of the lesion. The data were recorded in Microsoft Excel program. The outcome was measured in terms of complete, partial and non resolution of swelling.

RESULTS

A total of 50 cases were treated with intralesional doxycycline in six months duration. Eight cases lost to follow up so only 50 cases were included in the study. Among the 50 children, 31 were male and 19 were female.

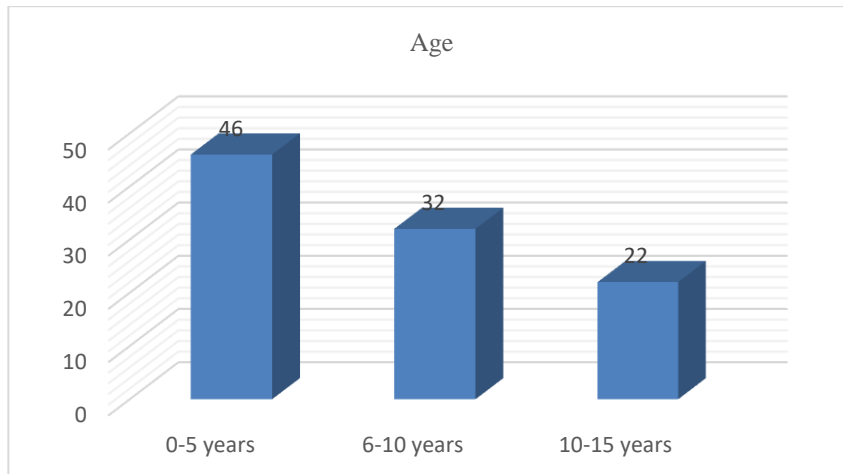


Fig-I: Age distribution of the study children

Table-1: Various sites of distribution of lymphangioma in children

Sites	Number of cases
Various compartments of neck	39
Face (cheek)	6
Oral cavity	3
Larynx	2

The commonest site of lymphangioma was neck followed by face (cheek), oral cavity and larynx (Table 1).

Ultrasonography showed mixed pattern in 35 cases (70.0%) whereas predominantly macrocystic pattern was seen in 9 cases (18.0%) and predominantly microcystic pattern was seen in 6 cases (12.0%) (Fig II).



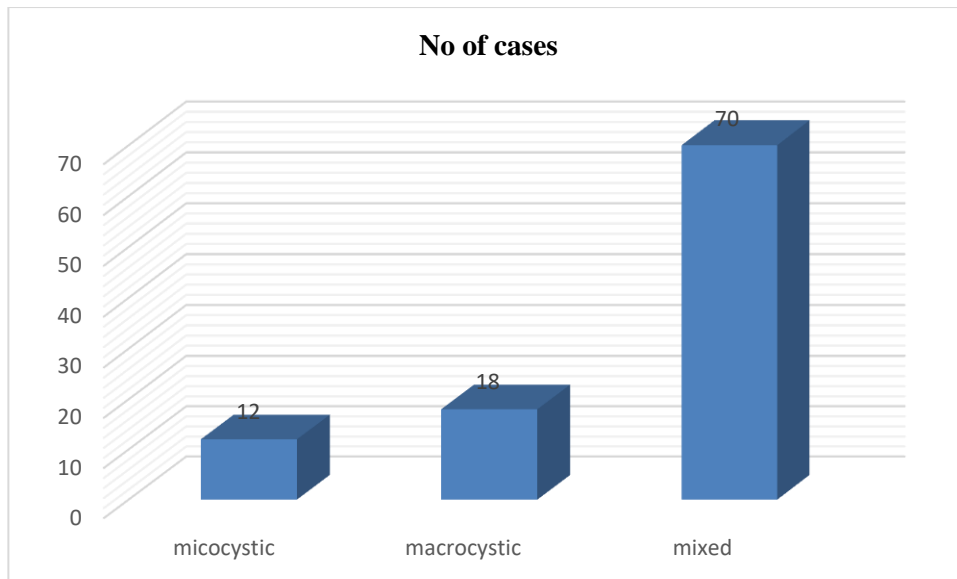


Figure-II: Ultrasonographic findings of Lymphangiomas

Table-2: Outcomes of Doxycycline sclerotherapy

Outcome after doxycycline injection	No of cases
Complete resolution of swelling	6 (12.0%)
Partial resolution of swelling	31 (60.0%)
No change in size of swelling	13 (26.0%)

There was complete disappearance of the macrocystic lesion in four cases after two sessions of Doxycycline injection. Partial resolution of the swelling occurred in

31 cases with mixed type of lymphangioma. In 13 cases, there was no change in the size of swelling (Table 2).

Table 3: Complications of Doxycycline sclerotherapy

Complications	No of cases
Erythema and swelling at the injection	31 (62.0%)
Secondary infection	13 (26.0%)
Fever	6 (12.0%)

Erythema and swelling at the site of injection were observed in 31 cases which disappeared after 24-72 hours. Secondary infection was seen in 13 cases which

got resolved with antibiotics. In six cases, patients developed fever after injection which resolved within 24 hours (Table 3).

DISCUSSION

Doxycycline may cause permanent discoloration of the teeth and slow down the growth of bones. This medicine should not be given to children 8 years of age and younger (except for the treatment of exposure to inhalational anthrax or rickettsia infection), unless directed by the child's doctor. Lymphangiomas are common vascular malformation in the pediatric population, and over 50% occur within the head and neck region. [14-16] Due to their location in the head and neck, lymphangiomas may cause cosmetic and functional morbidity. Traditionally, surgery was considered the standard of treatment for lymphangiomas but it is deferred now a day owing to the numerous complications including cranial nerve injury, malocclusion, and poor cosmetic results. According to Kennedy *et al.* the rate of complications increased from 17% in stage I lesions to 100% in stage

V lesions.[16] A range of sclerosing agents are being used to treat lymphangioma and Doxycycline is one of them. It is considered as one of the good options for treating lymphangioma as it is widely available and relatively cheap. Considering this fact, we evaluated the efficacy of Doxycycline as a sclerosing agent for head and neck lymphangioma in the pediatric population. In this study, we observed that lymphangioma was more common in children less than 5 years of age. Similar finding was observed by Nehra *et al.*, where the mean age of the children was 5 months with a range from 2 days to 21 months.[15] A study by Shergill *et al.* showed the mean age at the first treatment session was 5.9 years.[17] Lymphangioma can involve various parts of the body. It can involve multiple sites as reported by Nehra *et al.* [15] In our study, we observed that the most common site of involvement was neck followed by face (cheek), oral cavity and larynx. Laryngeal

lymphangioma presented with hoarseness and occasional difficulty in breathing which partially resolved after 2 sessions of doxycycline injection. Various Doxycycline sclerotherapy dose regimens are used in different studies. In our study, we used injection Doxycycline 10mg/ml and it was injected at multiple sites after aspirating the fluid. We used a dose of 100–800mg per session, depending on the age and weight of the child. Cordes *et al.* used Doxycycline in concentrations of 5 to 20 mg/mL which was delivered via a drainage catheter.[11] We found that mixed lesions (70.0%) were more common than macrocystic (18.0%) and microcystic lesion (12.0%). There was complete disappearance of the macrocystic lesion in four cases after two sessions of Doxycycline injection. Partial resolution of the swelling occurred in 31 cases with mixed type of lymphangioma. In 13 cases, there was no change in the size of swelling. Studies have shown varied responses with Doxycycline injection. Cordes *et al.* demonstrated an improvement (complete resolution or marked reduction) of lymphangiomas after percutaneous injection of doxycycline in almost all followed up patients.[11] In the study by Nehra *et al.*, all seven patients with macroscopic lesions achieved complete clinical resolution, and the four patients with mixed lesions achieved partial clinical resolution.[15] This result was supported by the study of Shiels *et al.*[14] Jamal *et al.* reported 50% of their patients had complete resolution of their lymphatic malformation and 33% of the patients did not experience significant clinical improvement or developed a recurrence at the endpoint of the study.[18] Cheng J got an encouraging overall success rate of 84.2% with Doxycycline sclerotherapy treatment in children with lymphatic malformation of the head and neck.[19] Various other literatures also have established 70-100% efficacy of Doxycycline sclerotherapy. [8,20,21] Erythema and swelling at the site of injection were observed in 31 cases which disappeared after 24-72 hours. Secondary infection was seen in 13 cases which got resolved with antibiotics. In six cases, patients developed fever after injection which resolved within 24 hours. Similar complication was observed by Cordes *et al.* [11] They speculated that risks associated with Doxycycline were local erythema, edema, and pain at the injection site. Other literatures had reported more serious complications, Burrows *et al.* reported a case of Horner syndrome after injection of doxycycline into a cervical lymphangioma.[22] A low sample size was one of the drawbacks of our study. Also, due to the unavailability of Doxycycline in infusion form while the study was being conducted, we had to rely on powered form for sclerotherapy. In our opinion, use of sterile infusion form could have further reduced the cases with secondary infection.

CONCLUSION

In concluded, doxycycline sclerotherapy proved to be safe and effective for the treatment of head and neck lymphangiomas in the pediatric population. DS has distinct

advantages over other sclerotherapy agents including that it is inexpensive and widely available, and has minimal side effects.

REFERENCES

1. Orvidas LJ, Kasperbauer JL. Pediatric Lymphangiomas of the Head and Neck. *Annals of Otolaryngology, Rhinology & Laryngology*. 2000;109(4):411-421.
2. Sichel JY, Udassin R, Gozal D, Koplewitz BZ, Dano I, Eliashar R. OK-432 therapy for cervical lymphangioma. *Laryngoscope*. 2004;114(10):1805-9.
3. Smith RJ. Lymphatic malformations. *Lymphat Res Biol*. 2004;2:25–31
4. Thomas DM, Wieck MM, Grant CN, Dossa A, Nowicki D, Stanley P, *et al.* Doxycycline sclerotherapy is superior in the treatment of pediatric lymphatic malformations. *J Vasc Interv Radiol*. 2016; 27:1846–1856.
5. Smith MC, Zimmerman MB, Burke DK, Bauman NM, Sato Y, Smith RJ. Efficacy and safety of OK-432 immunotherapy of lymphatic malformations. *Laryngoscope*. 2009;119(1):107-115.
6. Bloom DC, Perkins JA, Manning SC. Management of lymphatic malformations. *Curr Opin Otolaryngol Head Neck Surg*. 2004;12(6):500-504.
7. Balakrishnan K, Perkins J. Management of head and neck lymphatic malformations. *Facial Plast Surg*. 2012;28(6):596-602.
8. Molitch HI, Unger EC, Witte CL, van Sonnenberg E. Percutaneous sclerotherapy of lymphangiomas. *Radiology*. 1995;194(2):343-347.
9. Giguere CM, Bauman NM, Sato Y, *et al.* Treatment of lymphangiomas with OK-432 (Picibanil) sclerotherapy: a prospective multi-institutional trial. *Arch Otolaryngol Head Neck Surg*. 2002;128(10):1137-44.
10. Won JH, Kim BM, Kim CH, *et al.* Percutaneous sclerotherapy of lymphangiomas with acetic acid. *J Vasc Interv Radiol*. 2004;15(6): 595-600.
11. Cordes BM, Seidel FG, Sulek M, Giannoni CM, Friedman EM. Doxycycline sclerotherapy as the primary treatment for head and neck lymphatic malformations. *Otolaryngol Head Neck Surg*. 2007;137(6):962-964.
12. Hurewitz AN, Wu CL, Mancuso P, Zucker S. Tetracycline and doxycycline inhibit pleural fluid metalloproteinases. A possible mechanism for chemical pleurodesis. *Chest*. 1993; 103:1113–1117.
13. Matthew P. Lungren, Manish N. Patel. Endovascular Management of Head and Neck Vascular Malformations. *Current*



- Otorhinolaryngology Reports. 2014;2(4): 273–284.
14. Shiels WE, 2nd, Kang DR, Murakami JW, Hogan MJ, Wiet GJ. Percutaneous treatment of lymphatic malformations. *Otolaryngol Head Neck Surg.* 2009;141(2):219-224.
 15. Nehra D, Jacobson L, Barnes P, Mallory B, Albanese CT, Sylvester KG. Doxycycline sclerotherapy as primary treatment of head and neck lymphatic malformations in children. *J Pediatr Surg.* 2008;43:451–460
 16. Kennedy TL, Whitaker M, Pellitteri P, Wood WE. Cystic hygroma/lymphangioma: a rational approach to management. *Laryngoscope.* 2001;111(11 Pt 1):1929-37.
 17. Shergill A, John P, Amaral JG. Doxycycline sclerotherapy in children with lymphatic malformations: outcomes, complications and clinical efficacy. *Pediatr Radiol.* 2012;42(9):1080-8.
 18. Jamal N, Ahmed S, Miller T, Bent J, Brook A, Parikh S, Ankola A. Doxycycline sclerotherapy for pediatric head and neck macrocystic lymphatic malformations: a case series and review of the literature. *Int J Pediatr Otorhinolaryngol.* 2012;76(8):1127-31.
 19. Cheng J. Doxycycline sclerotherapy in children with head and neck lymphatic malformations. *J Pediatr Surg.* 2015;50(12):2143-6.
 20. Alomari AI, Karian VE, Lord DJ, Padua HM, Burrows PE. Percutaneous sclerotherapy for lymphatic malformations: a retrospective analysis of patient- evaluated improvement. *J VascInterv Radiol.* Oct 2006;17(10):1639-1648.
 21. Cahill AM, Nijs E, Ballah D, Rabinowitz D, Thompson L, Rintoul N, Hedrick H, Jacobs I, Low D. Percutaneous sclerotherapy in neonatal and infant head and neck lymphatic malformations: a single center experience. *J Pediatr Surg.* 2011;46(11):2083-95.
 22. Burrows PE, Mitri RK, Alomari A, *et al.* Percutaneous sclerotherapy of lymphatic malformations with doxycycline. *Lymphat Res Biol.* 2008; 6:209–216.