

## Case Report

DOI: 10.62046/gijams.2025.v03i02.001

### Autotransplantation of Surgically Removed Maxillary Impacted Canine, Complications and Prognosis

Nazih Shaban Mustafa<sup>1\*</sup>, Haszelini Binti Hassan<sup>2</sup>

<sup>1</sup>Associate Professor, Department of Oral Maxillofacial Surgery and Oral Diagnosis, Kulliyyah of Dentistry, International Islamic University Malaysia, Kuantan, Pahang, Malaysia

<sup>2</sup>Assistant Professor, Department of Oral Maxillofacial Surgery and Oral Diagnosis, Kulliyyah of Dentistry, International Islamic University Malaysia, Kuantan, Pahang, Malaysia

\*Corresponding Author: Nazih Shaban Mustafa | Received: 26.01.2025 | Accepted: 06.03.2025 | Published: 08.03.2025

**Abstract:** Autotransplantation of surgically removed maxillary impacted canines is a practical treatment option for patients with impacted teeth, particularly when eruption of tooth is unbearable. This case study involves the surgical extraction of the impacted canine and its transplantation into a prepared socket in the right side of maxilla. While autotransplantation offers several advantages, including preservation of alveolar bone and natural aesthetics, it is associated with potential complications such as root resorption, ankylosis, pulp necrosis, and periodontal attachment loss.

**Keywords:** autotransplantation, surgical, impacted canine, complications, prognosis.

**Citation:** Nazih Shaban Mustafa *et al.* Autotransplantation of Surgically Removed Maxillary Impacted Canine, Complications and Prognosis. Grn Int J Apl Med Sci, 2025 Mar-Apr 3(2): 35-39.

## INTRODUCTION

Tooth transplantation is an advanced dental procedure in which a tooth is relocated from one site to another in the same individual, this technique is often used to address cases of tooth loss, malposition, or impaction, particularly when other restorative options like implants or bridges are not feasible or desirable. The procedure is typically considered when a natural tooth can be salvaged from a donor site within the patient's own mouth, ensuring both biological compatibility and aesthetic outcomes [1].

In cases of impacted or malposed teeth, such as the upper canine, transplantation offers a unique alternative to more conventional treatments. The upper canine is particularly significant due to its key role in occlusion, speech, and facial aesthetics, making its proper positioning crucial for overall dental and facial harmony. Tooth transplantation can be particularly beneficial when the canine is impacted, or when the tooth's eruption is delayed or impaired, resulting in an abnormal position within the arch [2].

The success of tooth transplantation largely depends on several factors, including the condition of the tooth, the donor site, and the timing of the procedure. When successful, the transplanted tooth integrates into its new position, often offering a long-term solution without the need for artificial replacements. However, as with any

surgical procedure, careful planning and management of post-operative care are critical to ensure a favourable outcome [3].

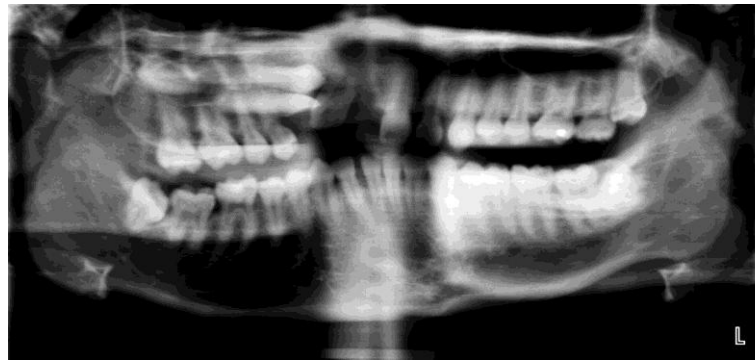## CASE REPORT

A 17 - year - old male patient attended the oral surgery specialist clinic at the Faculty of Dentistry International Islamic University Malaysia (IIUM) with the complaint of missing upper anterior teeth. Intra oral examination revealed missing teeth 11, 12, and 13 with mild non tender labial bulging and normal colour of the over lying mucosa.

## CASE HISTORY

A 17 - year - old male patient with the complaint of missing anterior teeth revealed a history of trauma but he cannot remember when. Extra oral examination showed no asymmetry or any abnormality, intral - oral examination demonstrated localized mild labial bony elevation adjacent to the area of tooth 12,13. Patient sent for orthopantomogram (OPG) Figure-1, which showed impacted teeth 11,12,13. The patient and parent informed about the case and given the treatment option. The treatment plan was surgical removal of the impacted teeth with the possibility of transplantation especially for the canine depending on the surgical procedure, and the condition of the tooth in addition to the surgical procedure which will be performed, avoiding any sectioning to facilitate the process of

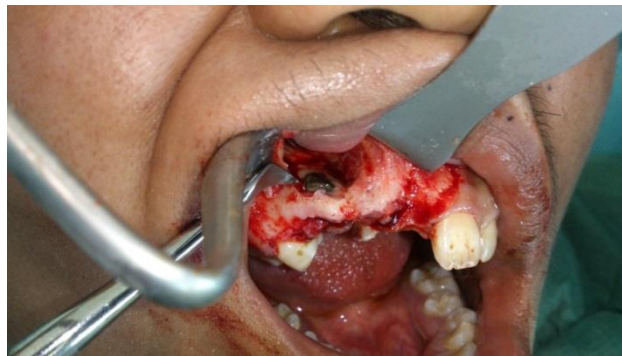transplantation. The patient's parent consented to the procedure and was scheduled for the surgical intervention.



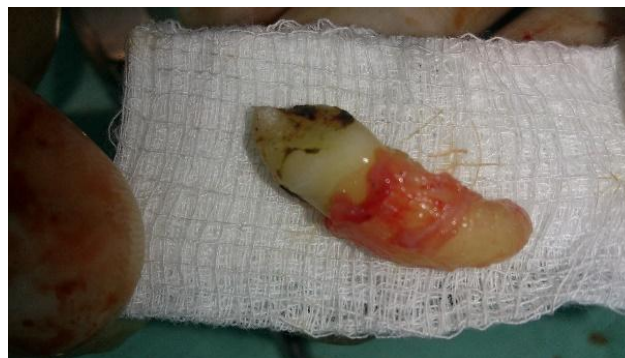**Figure-1: showing the impacted teeth**

The surgery was performed under local anesthesia, successfully removal of the canine without the need for sectioning. The surgical approach prioritized the

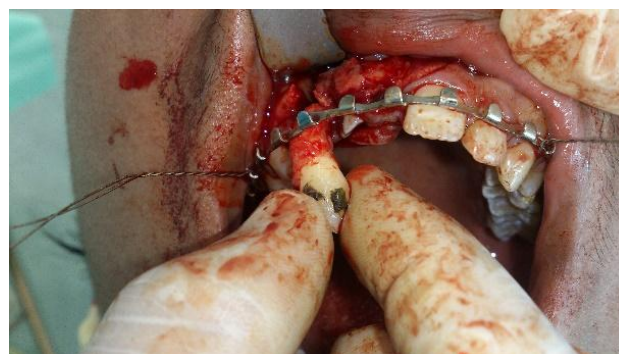preservation of bone volume, particularly the alveolar process rim as shown in Figure-2, to ensure adequate surrounding support for the transplanted tooth.



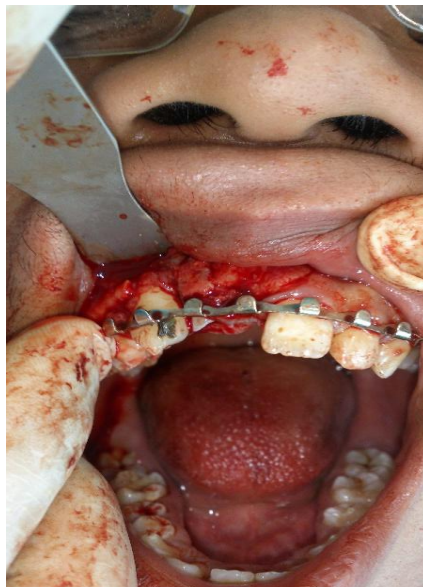**Figure-2: Surgical field**



**Figure-3: the extracted canine**



**Figure-4: placement the canine in the prepared socket**



**Figure-5: Fixation by using arch bar**

The socket was prepared for transplantation to match the length and width of the tooth. The tooth was then carefully inserted into the prepared socket and secured, as shown in Figure-5.

Postoperatively, the patient was prescribed with the necessary medications and provided with detailed instructions on maintaining oral hygiene, avoiding hard foods, and adhering to a soft diet.

The sutures were removed after one week; the wound healing was good with no signs of infection or swelling. The fixation period lasted four weeks, during which the patient was scheduled for weekly follow-up to monitor stability and address any potential complications.

During these visits, it was observed that the patient's oral hygiene ranged from fair to poor. Each time, oral hygiene instructions were reinforced, emphasizing that the survival prognosis of the transplanted tooth heavily dependent on proper hygiene.

At the fourth-week follow-up, mild tooth mobility was detected, leading to an extension of the fixation period

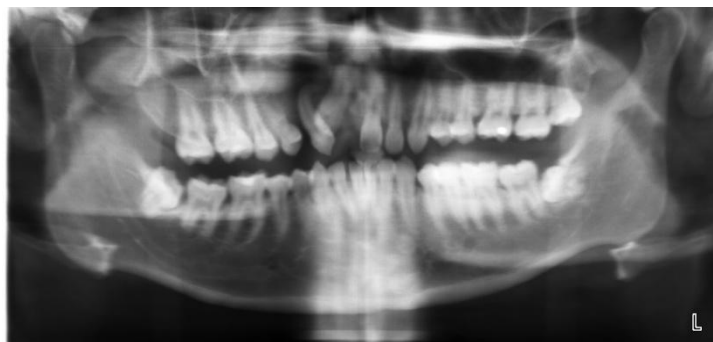
by two additional weeks. The patient was again reminded of the importance of maintaining good oral hygiene.

At the final visit, the arch bar was removed, and the tooth exhibited good stability with no signs of mobility. The patient was advised to continue a soft diet for another two weeks. A follow-up appointment confirmed that the tooth remained stable, with no signs of infection or pain.

The patient was scheduled for monthly follow-up appointments; however, he did not attend as planned and returned to the clinic after six months, complaining of tooth mobility and tenderness.

An OPG (Figure-6) was taken, revealing significant bone resorption around the transplanted tooth. The extent of the resorption indicated the need for extraction.

The tooth was extracted, with curation. The patient was prescribed with anti-inflammatory medication and painkillers.



**Figure 6: The bone resorption surrounding the transplanted canine**

## DISCUSSION

Historically, dental transplantations have been practiced for centuries, with modern techniques dating back to the mid-20th century, during which the success rates have significantly improved due to advances in surgical techniques, grafting methods, and post-transplantation care [4]. The success of tooth transplantation largely depends on factors such as the age of the patient, the condition of the donor tooth, the surgical technique employed, and the post-operative management [5]. In addition to that the stage of root development, atraumatic handling, and post-operative care. Long-term studies suggest that with proper case selection and follow-up, autotransplanted canines can achieve functional and aesthetic integration, offering a promising alternative to prosthetic or implant-based solutions.

One of the key challenges in transplantation of the upper canine is ensuring that the transplanted tooth integrates successfully with the recipient site, both functionally and aesthetically. The periodontal ligament (PDL), which plays a crucial role in the tooth's attachment to the bone, must be preserved during extraction to increase the chances of successful integration [6].

In recent years, there has been increased interest in improving the predictability of tooth transplantation, incorporating techniques such as root resorption prevention and the use of biomaterials to enhance healing and regeneration. As the field evolves, it is likely that the transplantation of the upper canine will continue to be an important alternative in the management of tooth loss, providing patients with a natural and viable solution.

This case report explores the indications, complications, and prognosis of autotransplanted maxillary canines to provide a comprehensive understanding of the procedure's effectiveness in clinical practice. Studies have shown that the transplantation of teeth, including the upper canine, can yield favorable outcomes when these biological factors are carefully considered, and when the procedure is performed under optimal conditions [3].

The causes of unsuccessful tooth transplantation remain uncertain and can vary from case to case. However, it is widely agreed that infection control is the top priority in any surgical procedure, alongside proper case selection. Evaluating the patient's oral hygiene is crucial in determining whether to proceed with surgery. This principle also applies to implant placement—if a patient has poor oral hygiene, the procedure should not be performed, even if the patient requests it.

Upon examination, the patient was found to have fair (but not good) oral hygiene. Regardless, in this case study, the patient attended the clinic complaining of missing or delayed eruption of anterior teeth and was

seeking a treatment plan. After evaluating the case, we proposed several treatment options. When tooth transplantation was mentioned as one of the possibilities, the patient was pleased with the option and willingly accepted it.

We discussed the importance of oral hygiene with the patient, explaining that it would account for approximately 50% of the procedure's success. Unfortunately, during the follow-up visits in the first two weeks after surgery, it became evident that the patient was not adhering to the prescribed oral hygiene instructions. This neglect led to periodontal issues, which may have been a primary cause of the procedure's failure. This finding aligns with previous studies emphasizing the critical role of post-operative oral care in the success of tooth transplantation [7].

## CONCLUSION

Autotransplantation of the maxillary canine effectively replaced a missing tooth in a young adult patient, preserving alveolar bone and function. With proper case selection and surgical technique, this method remains a valuable option for tooth replacement. A thorough evaluation of indications and contraindications is essential in determining the prognosis of the case. Proper case selection ensures a higher likelihood of success and minimizes potential complications.

**Acknowledgement:** The authors acknowledge the research project ID: SRCG20-012-0012 for the financial support.

## REFERENCES

1. Wang L, Jiang H, Bai Y, Luo Q, Wu H, Liu H. Clinical outcomes after intentional replantation of permanent teeth: A systematic review. *Bosn J Basic Med Sci.* 2020 Feb 5;20(1):13-20. doi: 10.17305/bjbm.2019.3937. PMID: 30684952; PMCID: PMC7029209.
2. Kobayashi, M., Watanabe, T., & Matsumura, T. (2019). Modern techniques in dental transplantation: A review of recent advancements. *International Journal of Oral Science*, 11(1), 15-24.
3. Yamada, T., Kawai, N., & Okada, H. (2017). Tooth transplantation: An update on the management and outcomes. *Journal of Clinical and Experimental Dentistry*, 9(7), e869-e875.
4. Kobayashi, M., Watanabe, T., & Matsumura, T. (2019). Modern techniques in dental transplantation: A review of recent advancements. *International Journal of Oral Science*, 11(1), 15-24.
5. González, S., Moreno, L. M., & Navarro, M. (2016). Transplantation of the upper canine: clinical and radiographic outcomes. *Journal of Clinical Periodontology*, 43(5), 423-429.



6. Naitoh, M., Shibata, S., & Ueno, T. (2015). The influence of the periodontal ligament on the survival of transplanted teeth. *Journal of Periodontology*, 86(10), 1127-1134.
7. Züger, M., Mulkadam, K., Filippi, A., & Schmidlin, P. R. (2024). Periodontal status after autologous tooth transplantation (ATT) of premolars and wisdom teeth: A systematic review. *SWISS DENTAL JOURNAL SSO – Science and Clinical Topics*, 134(4), 54-71. <https://doi.org/10.61872/sdj-2024-04-05>.